

A DISEASE REVIEW ON *BADDAGUDODARA*: INTESTINAL OBSTRUCTION W.S.R TO SIGMOID AND CAECAL VOLVULUS

Adithya J V ¹,

Siddayya Aradhyamath ²

¹P G Scholar , Dept. of Shalya Tantra, JSS Ayurveda Medical College, Mysore

²Reader and HOD, Dept. of Shalya Tantra, JSS Ayurveda Medical College, Mysore

ABSTRACT

The term volvulus is derived from the Latin word *volvere* (“to twist”). Cases of volvulus were described in ancient Egypt as early as 1550 BC. It occurs most frequently in Africa, the Middle East and India. Rates of volvulus in the United States are about 2–3 per 100,000 people per year. Sigmoid and caecal volvulus typically occurs between the ages of 30 and 70. A colonic volvulus occurs when a part of the colon twists on its mesentery, resulting in acute, sub acute, or chronic colonic obstruction. The main types of colonic volvulus are sigmoid volvulus and caecal volvulus. Diagnosing the potentially life-threatening conditions that present with gastrointestinal symptoms is itself a challenging job for a surgeon. Before the 19th century, management of patients with volvulus was largely expectant. Gradually, as nonintervention became associated with a high mortality, early surgical treatment became a widely accepted practice. Patients with volvulus are commonly elderly, debilitated, and bedridden. Often, the patient has a history of dementia or neuropsychiatric impairment. The patient may describe previous episodes of abdominal pain, distention, and obstipation, which suggest repeated subclinical episodes of volvulus. Disease entity Volvulus can be closely compared with *Badda Gudodara* as explained in classics and it has been told by *Acharyas* as *Shastra sadhya* and also *Asadhya vyadhi* as during those times prognosis of the disease was poor. Surgical intervention was mentioned to treat *Baddha Gudodara* , which contemplates the severity of the disease as well as excellence in the field of surgery by our *Great Acharyas* thousands of years back.

Keywords: Sigmoid Volvulus, Caecal Volvulus, Colon, *Baddhagudodara*, Mesocolon , Caecum

INTRODUCTION: *Udara*, a disease entity as told by our great *Acharyas* and other classics of *Ayurveda*, is a disease entity which can be closely correlated to number of abdominal distension diseases. One among the subtypes explained under *Udara* is *Baddha Gudodara*. *Baddha gudodara* has been explained in detail, by *Acharya Sushruta* in his treatise *Sushruta Samhitha*. He explains *baddha gudodara* with a very elaborate *Nidana*(Pathology) , *Laxanas* (Signs and Symptoms), *Samprapthi* (Pathophysiology) and *Chikitsa* (Treatment) wherein, its surgical management has been explained

in detail , which is the highlight of the *Sushruta’s* surgical expertise in conducting open abdominal surgeries during his era.

The term volvulus is derived from the Latin word *volvere* (“to twist”). A colonic volvulus occurs when a part of the colon twists on its mesentery, resulting in acute, sub acute, or chronic colonic obstruction. The main types of colonic volvulus are sigmoid volvulus and caecal volvulus ^[1,2]. Patients with volvulus are commonly elderly, debilitated, and bedridden. Often, the patient has a history of dementia or neuropsychiatric impairment. The patient

may describe previous episodes of abdominal pain, distention, and obstipation, which suggest repeated subclinical episodes of volvulus. Disease entity Volvulus can be closely compared with *Badda Gudodara* as explained in classics and it has been told by *Acharyas* as *Shastra sadhya* and also *asadhya vyadhi* as during those times prognosis of the disease was poor^[3].

When the disease entity *Baddha gudadodara* is closely reviewed and studied, most of its Pathology, pathophysiology, signs and symptoms are very much similar to Volvulus and in specific can be closely related to Caecal and Sigmoid volvulus. In this article, a sincere attempt is made to bring *Baddhagudodara* and Volvulus on same lines as per the classics and Modern medicine respectively based on the above said parameters like Pathology, Patho physiology, signs and symptoms and finally surgical management. Also an effort is made to highlight the surgical management of *baddha gudodara* as told by *Sushruta* for its management.

Pathophysiology / Nidana: Chronic constipation in Western society and a high-fiber diet in developing nations lead to an overloaded sigmoid colonic loop. The weight of this loaded sigmoid colon makes it susceptible to torsion along the axis of the elongated mesentery. The presence of a gravid uterus or a large pelvic mass alters the relative positions of the intra-abdominal organs, also predisposing to formation of volvulus. As a result of repeated subacute attacks of torsion, the base of the sigmoid mesocolon becomes foreshortened. The associated mild, chronic inflammation at the base of the mesentery and the two limbs of the sigmoid colon loop leads to the formation

of adhesive tissue. This causes the sigmoid loop to become chronically fixed into a paddle like configuration, which, in turn, predisposes to recurrence of the torsion.^[5] Caecal volvulus may be organo-axial (true caecal or caeco colic volvulus) or mesentericoaxial (caecal bascule). The former involves the distal ileum and ascending colon twisting around each other, in much the same way as a sigmoid volvulus. Compared with sigmoid volvulus, in which the torsion is in a counterclockwise direction, caecal volvulus usually occurs in a clockwise direction. Incomplete caecal and ascending colonic fixation occurs because of a lack of embryologic development of the dorsal mesentery. The lack of development predisposes the patient to clockwise torsion of the caecum, terminal ileum, and ascending colon. Vascular compromise is common because of mesenteric torsion. A complete volvulus leads to the development of a closed-loop obstruction of the affected colonic segment. Increased dilation of the bowel loop compromises the vascular supply of the bowel, eventually leading to ischemic gangrene and bowel wall perforation.

*sudurbala agne ahitaashanasya
samshushka putyanna nishhevanaath vaa |
snehadimityaacharanaaccha
janthorvruddim gathaha
koshtamabhiprapanna ||^[6]*

As per *Ayurveda*, the *nidana* for the causation of the disease is said to be due to the person indulging in eating unwholesome food, eating dry food or putrid food, which leads to derangement of *doshas* leading to impaired digestion leading to *baddagudodara*. Eating unwholesome food can be correlated to the consumption of high fiber diet as explained by the Modern medicine.

ETIOLOGY : The presence of a long mesentery with a narrow base of fixation to the retroperitoneum and elongated, redundant bowel predisposes to the formation of volvulus. Volvulus can develop in any portion of the large bowel. However, it is most common in the sigmoid colon because of the mesenteric anatomy. Less commonly, volvulus develops in the right colon and terminal ileum (caecal or caecocolic volvulus) or the caecum alone (termed a caecal bascule). In rare cases, volvulus may develop in the transverse colon or the splenic flexure. Also loaded colon due to high residue diet is another precipitating factor^[7]. In rare cases, old known cases of diverticulitis with a band or adhesions is another precipitating factor^[8]. In developing countries, a high-fiber diet leads to overloading of the sigmoid colon, which twists around its mesentery and results in volvulus. Megacolon, either congenital or acquired through Chagas disease, predisposes to the development of sigmoid volvulus. In areas of South America where Chagas disease is endemic, the development of sigmoid volvulus in affected patients is reported to be as high as 30%.^[9] Patients suffering or who has suffered from appendicitis with resultant formation of adhesions, predisposes to caecal volvulus as well. Likewise cases with history of the following conditions are predisposed to development of Sigmoid or caecal volvulus

- a) Pelvic space-occupying lesion
- b) A gravid uterus
- c) Ovarian tumor
- d) Gaseous dilation of the sigmoid colon and caecum after colonoscopy
- e) Postoperative adhesions
- f) Internal herniations
- g) Intussusceptions

- h) Omphalomesenteric abnormalities
- i) Intestinal malrotations,
- j) Carcinoma

Sigmoid volvulus is a definite occurrence in mentally disturbed patients, hypothyroidism, parkinsons disease, multiple sclerosis etc probably due to severe constipation due to medications,^[10]

Epidemiology:

Worldwide geographic variations in the incidence of sigmoid volvulus are well described. Much higher frequencies are reported in African, Asian, Middle Eastern, Eastern European, and South American countries. In all of these regions, the inhabitants consume a high-fiber diet, which is considered a predisposing factor for the development of sigmoid colon volvulus. In these endemic areas, patients are younger and predominantly male.

In the “volvulus belt” of Africa and the Middle East, nearly 50% of large-bowel obstructions are a result of volvulus, almost exclusively of the sigmoid colon. Caecal volvulus is much less common than sigmoid volvulus, accounting for 10-15% of all cases of volvulus and predominately affecting women in the sixth decade of life. In India, it most commonly seen in northern India particularly in the states of Punjab and Haryana.^[11]

Clinical Presentation:

Patients with volvulus are commonly elderly, debilitated, and bedridden. Often, the patient has a history of dementia or neuropsychiatric impairment. As a result, only a limited history is available.

The symptoms may be acute (60-70%), sub acute or chronic

- Chronic constipation
- Episodes of abdominal pain
- Massive abdominal distension
- Nausea

- Vomiting
- Hypotension
- Bloating sensation of abdomen
- Peritonitis
- Septicemia
- Shock
- Respiratory discomfort (Due to massive abdominal distension)
- Cardiovascular Compromise

The presentation of volvulus is much the same, regardless of its anatomic site. Cramping abdominal pain, distention, obstipation and constipation are present. With progressive obstruction, nausea and vomiting occur. The development of constant abdominal pain is ominous and indicates the development of a closed-loop obstruction with significant intra luminal pressure. This, in turn, leads to the development of ischemic gangrene and bowel wall perforation.^[12]

Abdominal distention is commonly massive and characteristically tympanic over the gas-filled, thin-walled colon loop due to diffusion of CO₂. Due to gross distension, results in severe hypovolaemic shock within 6-8 hours of volvulus ^[13]. Gangrene sets in, which gives rise to features of strangulation. Overlying or rebound tenderness raises the concern of peritonitis due to ischemic or perforated bowel. Depending on the extent of bowel ischemia or fecal peritonitis, signs of systemic toxicity may be apparent. Because of the massive abdominal distention, the patient may have respiratory and cardiovascular compromise.

As per Ayurveda, the clinical manifestation of *Badda Gudodara* closely matches to almost all the signs and symptoms explained for Sigmoid and caecal volvulus.

*Yasyantra anne rupa lepirbhivaa
baalashmir bhava sahithaihi pruthagvaa |
Sancheeyathe tatra malaha sadoshaaha
kramena naadyamiva sankaro hi ||
Nirudyathe chaasya gude purisham nirothi
kruchradapi chalpamalpam |
Hrunaabimadhye parivruddhimethi
yachchodaram vitsamagandhikancha |
Pracchardyan baddagudi vibhavyaha ..||
[14]*

The fecal matter, mixed with the deranged *Vayu, Pitta* etc of the body lies stuffed in the rectum of a person whose intestines have been stuffed with slimy food etc. They give rise to a sort of dropsical swelling of the abdomen with tympanities due to the constriction of the intestine, more commonly seen in between the parts of heart and umbilicus, is known as *baddha gudodara*. Scanty stools are evacuated with greatest pain and utmost difficulty. The patient vomits a peculiar kind of matter with a distinct faecal smell. All the symptoms like Dropsical swelling of the abdomen, tympanities due to massive abdominal distension, scanty passage of stools or chronic constipation, feculent vomiting of abdominal contents which is seen when gangrene sets in and systemic toxicity sets in, are all the symptoms which can be closely correlated to signs and symptoms as explained above for sigmoid and caecal volvulus.

Differential Diagnosis :

a) Ileosigmoid knot : The differential diagnosis of colonic volvulus includes a rare condition known as an ileosigmoid knot. An ileo sigmoid knot occurs when the ileum and sigmoid colon become entangled, creating a knot that results in vascular compromise of the bowel. The patient presents with acute onset of abdominal pain and rapidly developing shock. Ileo sigmoid knot is a life-

threatening condition that requires urgent surgical treatment.

- b) Intussusception
- c) Peritonitis
- d) Obstructed hernia
- e) Worm Ball
- f) Mesenteric vascular torsion
- g) Faecal impaction
- h) Perforated Small bowel
- i) Perforated Large bowel

Investigations :

- Complete Blood Picture
- Serum Amylase
- Serum Lipase
- RFT
- LFT
- Serum Electrolytes
- Urine routine
- Plain X-ray abdomen : Shows dilated and distended sigmoid/caecal loop.
- USG Abdomen and Pelvis

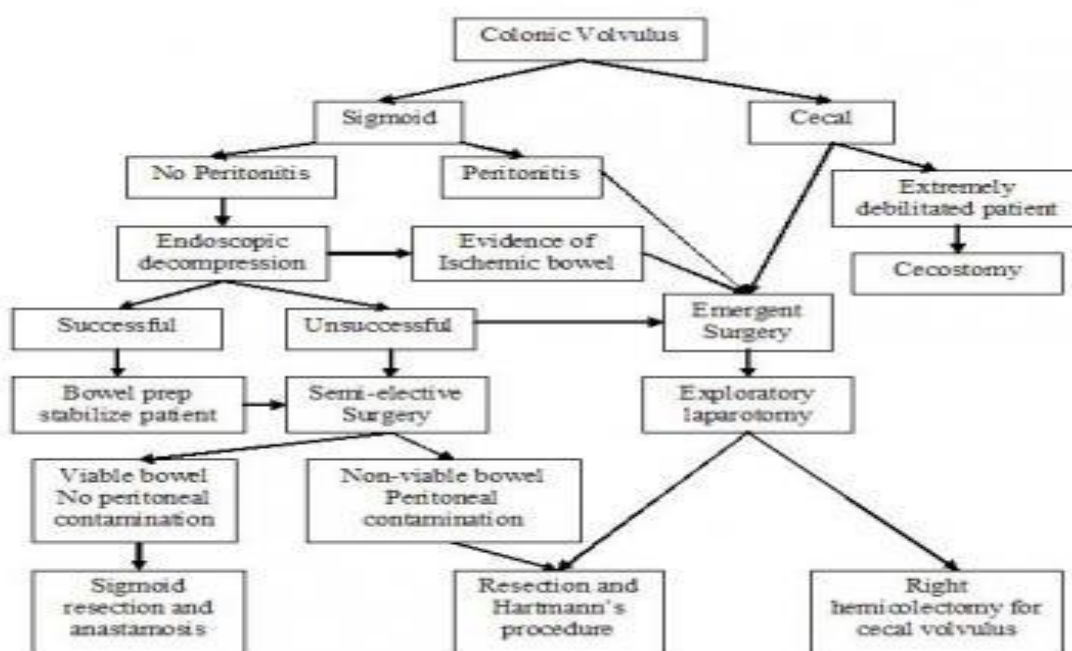
- Computed tomography (CT)
- Barium enema
- MRI
- Sigmoidoscopy or colonoscopy.

MANAGEMENT :

Non-Operative :

A successful passage of flatus tube or sigmoidoscope upto 25-30 cms results in release of large amount flatus and fluid and obstruction is relieved. If obstruction is completely relieved or if there is no gangrene and the general condition of the patient improves, an elective resection is done after 7 days. If resistance is found while passing flatus tube, instill barium for guidance.^[15]

Operative: Surgery is the definitive treatment of sigmoid and caecal volvulus. The decisions regarding timing of surgery and choice of procedure depend on the clinical presentation



Surgical methods commonly considered are as follows :

- Endoscopic detorsion and decompression

- Sigmoid colectomy for sigmoid volvulus
- Hartmann procedure for sigmoid volvulus

- Right hemicolectomy for caecal volvulus etc

Acharya Sushruta has explained surgical line of treatment for the treatment of *Baddha-gudodara*.

The line of treatment is as follows,

*Badhagude parisravini cha
snigdhasvinnasya abhyakthasya adho
nabhirvamatha chatvarungalapahaya
roma rajya udaram patayithva
chaturangula pramana anyatraani
nitkrushya nirikshya badhagudasya
aantrapratirodhakaramashmanam baalam
vaa aapavya mala jaatham va tatho
madhusarpibhya abhyanaja aantraani
yasthanam sthaapayithva vaahyam
vrana udarasya seevyeth* |^[16]

In cases of *baddagudodara*, the patient should be first treated with emulsive measure i.e. *snehana* and fomentation i.e. *swedana* is to be done. The *bahya sneha* should be applied. Then an incision should be made on the left side of the abdomen below the umbilicus and four fingers to the left of the line of the hair which stretches from downward from the navel. The intestine to the length of four fingers should be gently drawn out. Any obstructing matter should be removed, intestine twisted back into normal position, carefully examined and then the intestine should be moistened with honey and clarified butter. It should be gently replaced in its original position and the mouth of the incision in the abdomen should be sewn up. If at all there is leaking intestine i.e. perforated intestine vis.a.vis *parisravi udara*, the secreting intestine should be purified. The two ends of the severed intestine should be firmly pressed and adhered together and large black ants should be applied to these spots to grip them fastly with their mouth. Then the body of the ants having their heads firmly

adhering to the spots, as directed, should be severed and the intestines should be gently reintroduced into their original positions, sutured up as in the preceding case. The operated wound must be taken care of as per the management of *Vrana*. Here the concept of biodegradable sutures can be appreciated wherein the ants were used for suturing the internal organs. The concept of bio-absorbable or degradable suturing concepts mentioned here, throws light on the knowledge of our *acharyas* in understanding physiology of the bodies response and interaction with a foreign body. The reintroduction of body organs into its respective positions, closing of the abdomen after its opened up, identification of the twisted intestines, removal of any obstructive matter shows the surgical expertise of the surgeons of those days. More research is needed in understanding these procedures in detail and also to perform the above said surgical method of operation on the same lines as per the classics with the support of *sangyahaarana* needs to be done, in order to validate and scientifically establish this *Sushruta's* Surgical technique for the management of Volvulus, which glorify *Ayurveda*, the great science, that emergency surgical interventions and life saving surgeries did exist and were performed in *Sushruta's era*, which adds grandeur to India's contribution to the field of modern day surgery.

COMPLICATIONS:

Postoperative care includes continued fluid resuscitation and antibiotic therapy as guided by the patient's clinical condition. Possible postoperative complications include the following:

- Surgical wound infection (8-12%)
- Anastomotic leakage (3-7%)
- Colocutaneous fistula (2-3%)

- Abdominal or pelvic abscess (1-7%)
- Sepsis (2%)^[17]

DISCUSSION:

The incidence rate of sigmoidal and caecal volvulus is on increase in population of India due to the intake of a high-fiber diet in the developing nations, increased incidence rates of hernia, appendicitis, intra abdominal tumors etc. Thorough knowledge of the disease right from its etiology, epidemiology, pathophysiology, clinical presentation and its management is helpful for immediate diagnosis of the disease because of the severity of this disease.

As per *Ayurveda*, we can correlate the above said disease to *baddhagudodara* as explained by *Acharya Sushruta*. Complications of the above said disease when left untreated will lead to perforation and peritonitis due to which the *Acharya* have told it is an *asadhya vyadhi* wherein the signs and symptoms explained by our great *Acharyas* thousands of years ago can be compared and matched with the above disease entity. The severity of the disease is to be understood and timely surgical intervention as explained thousands of years ago by our *Acharyas* shows the advancements in the field of surgery and their expertise in treating the diseases.

CONCLUSION:

Understanding the disease entity volvulus is of prime importance, as occurrence of the above said disease is on increasing note, immediate and prompt diagnosis of the condition should be of utmost priority for a doctor from any allied branches as it is a life threatening – emergency medical condition. Hence, understanding the disease in its entirety will definitely help the medical fraternity and understanding the management principles accordingly will help in managing this disease with a

high success rate. Also it stresses upon the need to conduct more research to validate and scientifically establish *Sushruta's* surgical technique of management of Volvulus, which facilitates the scholars of *Shalya tantra* fraternity to perform gut / colon related surgeries.

REFERENCES :

- 1) Lianos G, Ignatiadou E, Lianou E, Anastasiadi Z, Fatouros M. Simultaneous volvulus of the transverse and sigmoid colon: case report. *G Chir.* 2012 Oct. 33(10):324-6. [Medline].
- 2) Elsharif M, Basu I, Phillips D. A case of triple volvulus. *Ann R Coll Surg Engl.* 2012 Mar. 94(2):e62-4. [Medline].
- 3) Sushruta, Sushruta SamhitaYadavji Tikramji, Choukambha Publication 1997 Varanasi, PP 458 chikitsa Sthana 14/3-4
- 4) Sushruta, Sushruta SamhitaYadavji Tikramji, Choukambha Publication 1997 Varanasi, PP 460 Chikitsa Sthana 14/ 28
- 5) <http://emedicine.medscape.com/article/2048554-overview#a5> dated at 30/08/2017
- 6) Sushruta, Sushruta SamhitaYadavji Tikramji, Choukambha Publication 1997 Varanasi, PP 295 Nidana Sthana 8/ 7-8
- 7) Rajgopal Shenoy, Manipal Manual of surgery, Volvulus of the sigmoid colon, pg no 495, second edition, 2005
- 8) Rajgopal Shenoy, Manipal Manual of surgery, Volvulus of the sigmoid colon – precipitating factors, pg no 496, second edition, 2005
- 9) <http://emedicine.medscape.com/article/2048554-overview#a6> dated 30/08/2017

- 10) Rajgopal Shenoy, Manipal Manual of surgery , Volvulus of the sigmoid colon – precipitating factors, pg no 496, second edition, 2005
- 11) Rajgopal Shenoy, Manipal Manual of surgery , Volvulus of the sigmoid colon – key box 30.8, pg no 495, second edition, 2005
- 12) <http://emedicine.medscape.com/article/2048554-overview#a6> dated 30/08/2017 Rajgopal Shenoy, Manipal Manual of surgery , Volvulus of the sigmoid colon – Clinical features , pg no 496, second edition, 2005
- 13) Sushruta, Sushruta Samhita Yadavji Tikramji, Choukambha Publication 1997 Varanasi, PP 296 Nidana Sthana 8/ 26-28
- 14) Rajgopal Shenoy, Manipal Manual of surgery , Volvulus of the sigmoid colon – Clinical features , pg no 496, second edition, 2005
- 15) Sushruta, Sushruta Samhita Yadavji Tikramji, Choukambha Publication 1997 Varanasi, PP 460 Chikitsa Sthana 14/ 20-21
- 16) <http://emedicine.medscape.com/article/2048554-overview#a6> dated 30/08/2017
- 17) Gordon, Philip H.; Nivatvongs, Santhat (2007). *Principles and Practice of Surgery for the Colon, Rectum, and Anus, Third Edition*

Corresponding Author:

Dr Adithya J V, P G Scholar , Dept. of Shalya Tantra, JSS Ayurveda Medical College, Mysore.

Email: adithya.jois@gmail.com

Source of support: Nil
Conflict of interest: None
Declared

Cite this Article as : [Adithya J V et al : A Disease Review on Baddagudodara: Intestinal obstruction W.S.R to Sigmoid and Caecal Volvulus] www.ijaar.in : IJAAR VOLUME III ISSUE VI JAN-FEB 2018 Page No:-993-1000