

A CASE STUDY ON ABHISHYANDA (INFECTIVE CONJUNCTIVITIS)

M.Ashwitha^{1*}

Sumithra T Gowda²

¹Post Graduate Scholar, ²Professor & HOD, Department of Shalaky Tantra, Government Ayurvedic Medical College, Bengaluru, Karnataka, India

ABSTRACT

Infective Conjunctivitis is one of the commonest types of conjunctivitis in developing countries. It can occur as sporadic and epidemic cases. Outbreaks of bacterial conjunctivitis epidemics are quite frequent during monsoon season. It needs immediate intervention of treatment as the complication includes superficial keratitis, marginal corneal ulcerations. *Seka*, *Vidalaka* and drugs having anti-inflammatory, anti-infective properties are used to relieve the condition and also to prevent the progress of the disease.

Keywords: *Seka*, *Vidalaka*, *Abhishyanda*.

INTRODUCTION: *Abhishyanda* is said to be the root cause of *sarva netra roga*. It is one of the *Aupasargika Vyadhi*¹ (Contagious disease). Measures to relieve the condition are given much importance as the progression may lead to serious conditions. Inflammation of the conjunctiva is Conjunctivitis which has hyperemia of conjunctiva and discharge may be watery, mucoid, purulent or mucopurulent. It accounts for 1% of all primary care consultation. Bacterial Conjunctivitis is more common in children².

CASE REPORT: A male patient of 32 yrs came to *Shalaky* O.P.D of Government Ayurveda Medical College, Bengaluru.

Main Complaint: Itching and Redness of left eye with swollen eyelids.

Duration: 2 days

History of Present Illness: A male patient was apparently normal 2 days back. He developed itching & redness of left eye. For this he had applied antibiotic ointment which he found no relief. The left eye had lid swelling, mucoid discharge, congestion. Even right eye showed mild changes. He consulted *Shalaky* O.P.D Government Ayurvedic Medical College for the better results.

Past History: Not k/c/o DM, HTN and other infectious diseases.

Family History: H/o of infection to his nephew in his home 5 days earlier.

General Examination: Nothing specific to this particular disease.

Ocular Examination:

Conjunctiva - Congestion, Chemosis

Eye lid - Edema and left eye was completely closed

Discharge - Purulent, thick

Cornea - small, pointed white lesions

Visual Acuity:

Right Eye- 6/6

Symptoms: Discomfort, Foreign Body sensation, Mild Photophobia

Mucopurulent Discharge, Sticking together of lid margin

Final Diagnosis: Infective Conjunctivitis.

TREATMENT: 7 days of *Seka*³ (Pouring stream of medicated decoction over the closed eye) and *Vidalaka*³ (Application of paste on the eyelid) with *Triphala* (*Emblica officinalis*, *Terminalia chebula*, *Terminalia bellerica*), *Yashti* (*Glycyrrhiza glabra*), *Lodhra* (*Symplocos Racemosa* Roxb) and *Daruharidra*⁴ (*Berberis aristata*). These drugs are mentioned in *vata and pittaja bhisnyanda ckikitisa*.

Internal Medicine -*Triphala Guggulu*1-0-1

Gandhaka Rasayana 1-0-1

OBSERVATIONS:

DAY	CHANGES
1 st & 2 nd Day	On application of <i>Vidalaka</i> , the discharge was draining out
3 rd , 4 th , 5 th Day	Swelling of lid and congestion had reduced and eye got opened partially.
6 th , 7 th Day	Complete opening of the eye was seen. Swelling, Discharge, Congestion had reduced upto 90%.

Visual Acuity:

	Before		After	
RE	6/6	N6	6/6	N6
LE	6/9	N8p	6/6p	N6p

After the above treatments patient had mild punctate lesions. The vision was almost normal but had blurriness in vision giving a masking effect. He was later advised for(after 10 days of treatment) :

Patoladi Ghrita Tarpana for 7 days and *Pushpa Varti Anjana* for 30 days. Later the complaint of blurriness got reduced.

DISCUSSION: Conjunctivitis is an inflammatory process. *Kriyakalpas* serve purpose in relieving the symptoms like watering, pain, swelling. *Seka* has more bioavailability and tissue contact time. It does the local vasodilatation. *Vidalaka* is a type of *lepa* around the closed eye except on lashes. It may help in aqueous drainage and indicated in inflammatory conditions³. The drugs *triphala*, *yashti*, *daruharidra* and *lodhra* was used for *Seka* and *Vidalaka*. *Daruharidra*, *triphala*, *yashti* are *chakshushya* (ocular protective). *Triphala* has Chebulagic acid which is antibacterial,anti-inflammatory⁴.

Yashtimadhu has glycyrrhizin which is anti-inflammatory, anti- bacterial, anti viral ⁵. The ethanol extract of *Lodhra* Bark has

analgesic, anti-inflammatory, anti-bacterial properties⁶. The berberine of *Daruharidra* has anti-microbial, anti-inflammatory activity⁷. *Pushpa Varti Anjana* is indicated for Corneal opacity⁸. The ingredients are *tila pushpa*, *jati pushpa*, *pippali*, *maricha*. These have anti inflammatory and *tila*, *jati pushpa* has antiangiogenetic property⁹. *Tarpana* with *Patoladi Ghrita* is pitta hara. Later *anjana* was carried out. Internal Medicine *Triphala guggulu* and *Gandhaka Rasayana* may serve as anti-inflammatory action.

CONCLUSION: Infective type of Conjunctivitis must be treated quickly in acute conditions. This if delayed and untreated has ill effects on cornea. The drugs and the modalities used has helped the patient in relieving his condition. According to its severity it must be treated. The signs & symptoms must be examined carefully. If cornea is extensively affected it must be treated with the help of biomedicine.

REFERENCES

1. Susruta. Susruta Samhita with Nibandha Sangraha Vyakhya by Dalhanacharya and Nyayachandrikhya Panjika Vyakhya by Gayadasa edited by vaidya Yadavaji Trikamaji, varanasi: chaukamba oriental; 2008. P. 259.
2. bestpractice.bmj.com/bestpractice/monograph/68/basics/epidemiology.html.10/7/2017
3. Sonil Kumar Rajendra. Srivastava Garima. Dhiman K.S. Kriyakalpa - A Broad way to treat eye diseases. WORLD JOURNAL OF PHARMACY AND PHARMACEUTICAL SCIENCES.
4. <https://en.wikipedia.org/wiki/Triphala>. Clinical Study of ‘Triphala’ – A Well Known Phytomedicine from India. Mukherjee K Pulok et al. 1735-

2657/06/51-51-54 Iranian Journal Of Pharmacology & Therapeutics Copyright © 2006 by Razi Institute for Drug Research (RIDR) IJPT 5:51-54, 2006. 11/7/2017

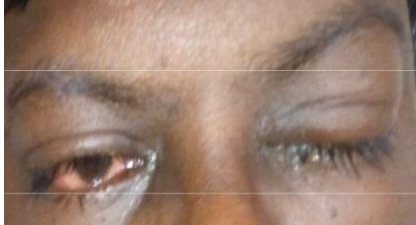5. <https://en.wikipedia.org/wiki/Glycyrrhizin>

6. <https://herbsandayurveda.wordpress.com/2012/12/.../yashti-madhu-glycyrrhiza-glabra>. 10/7/2017

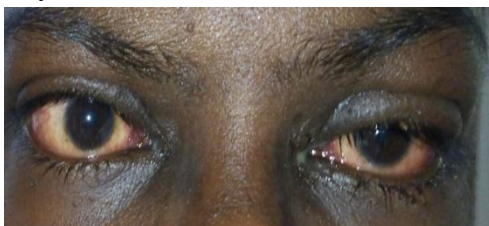
7. docsdrive.com/pdfs/pharmacologia/2014/76-83.pdf Phytopharmacological Profile of *Symplocos racemosa*: A Review. 14/7/2017

8. https://www.researchgate.net/publication/215483150_Berberis_aristata_A_Review. 15/7/2017

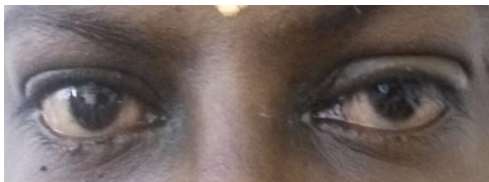9. Sharngadhara. Sharngadhara Samhita – with Adhamalla’s Deepika and Kashiram’s Gudārtha Dipika Commentary, Edited by Pandith Shastri Parashurama, 4th Ed. Varad- Day -1



Day-3



Day-7



nasi: Chaukhamba Orientalia; 2000. 398 pp.

10. <http://scialert.net/abstract/?doi=ijp.2010.616.623.20/7/2017>

Corresponding

Author:

Dr.M.Ashwitha, Post Graduate Scholar, Professor & HOD, Department of Shalakyā Tantra, Government Ayurvedic Medical College, Bengaluru, Karnataka, India. Email: ashwitha1991@gmail.com

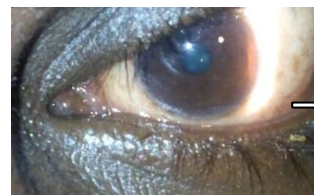
Source of support: Nil

Conflict of interest: None


Declared

Cite this Article as : M.Ashwitha et al :A Case Study on Abhishyanda (Infective Conjunctivitis): IJAAR VOLUME III ISSUE III JUL-AUG 2017 Page No:528-530

After the Anjana



Before Pushpavarti Anjana



Govt. Ayurvedic Medical College, Bangalore Government Ayurvedic Medical College, Bangalore Institute of Indian Medicine Bangalore-59		
Patient Slip Hospital No. / OP No. / Annual: 10153 / Date: 14/8/17 Dept./Daily: 33 Dept./Dept.: 9		
Patient Name: Harinath Age: 32 Sex: M Mar. Status: HMP Address and Phone No.: Monthly Income:		
Date: / / Disease:		
Date 14/8/17	Signs & Progress 1) Left eye lid swelling 2) Discharge - Pus 3) Right eye	Treatment 1) Pushpavarti 2) Triphala chakras 3) Triphala chakras