



## AYURVEDIC MANAGEMENT OF CENTRAL SEROUS RETINOPATHY - A CASE STUDY

<sup>1\*</sup>G R Shwetha

<sup>2</sup>Sreedhar Suja k

<sup>1</sup>Post Graduate Scholar, Department of Shalakya Tantra, Government Ayurvedic Medical College, Bengaluru, Karnataka, India.

<sup>2</sup>Professor, Department of Shalakya Tantra, Government Ayurvedic Medical College, Bengaluru, Karnataka, India.

### ABSTRACT

Central serous retinopathy (CSR) is also known as central serous chorio retinopathy (CSCR), is a visual impairment condition characterised by fluid accumulation resulting in a localized macular detachment and blurred vision or distorted central vision. The underlying pathogenesis revolves around functional or structural defect in the fluid-pumping capabilities of the retinal pigment epithelium (RPE) and choroidal vascular stasis or hyperpermeability. Complete resolution occurs in most of the patients in three to six months but most of the patients unwilling to wait or in those with immediate occupational demand. Observation and laser photocoagulation are the only treatment in contemporary science. This condition shows the feature *Vimarga gamana* and vitiation of *Vata pradhana Pitta-Kapha dosa* so treatment is planned according to *Samprapti* of the disease, A 46 year old male patient with central serous retinopathy showed marked improvement in ayurvedic management is presented in this article.

**Keywords:** Central serous retinopathy, Hyperpermeability, *Vimarga gamana*, *Vata pradhana Pitta-Kapha dosa*.

**INTRODUCTION:** Central serous retinopathy is an Idiopathic disorder characterized by a localized serous detachment of the sensory retina at the macula secondary to leakage from the choriocapillaries through one or more hyper permeable RPE sites. CSR typically affects one eye of a young or middle (20-50 years) aged, males more than females<sup>1</sup>. The Incidence of CSR is said to be 10 in 100,000. There does not appear to be any clear predisposing factors<sup>2</sup>, Imperfectly defined risk factors include Steroid administration, Helicobacteria pylori infection, Pregnancy, Psychological stress and Sleep apnoea syndrome. Clinical features are unilateral blurring, metamorphopsia, micropsia and mild dyschromatopsia signs are round or oval detachment of the sensory retina at the

macula, subretinal fluid may be clear or turbid.

Management is observation, Laser to the RPE site of the retina, Photodynamic therapy (PDT), Intravitreal anti-VEGF agents<sup>[1]</sup> but in observation, duration is long (3-6 months) patient may unwilling and remaining methods are expensive and has their own complications such as Geographic atrophy of the pigment epithelium and choriocapillaris, fibrovascular scar etc<sup>3</sup>.

Ayurveda is mainly based on *Tridosha siddhantha*<sup>4</sup> any disease can be treated on the basis of this, the Etiopathogenesis involves due to *Nidana* [causative factor] *Chinta* [excessive thinking, stress etc] diabetes, vitiation of *vata*, *pitta* and *kapha* leading to *rasa* and *raktavaha srotodusti*, *prasara* to the eye and *stana samsraya* in

*dristi* results in *shopha* in *drishti* (macula). In this case study patient shows good improvement by ayurvedic management.

#### MATERIALS AND METHODS:

##### CASE REPORT:

- **Chief complaint:** C/o Blurred vision in Right eye since one month.
- **History of present illness:** A 46 year old male patient with history of diabetes since 4 years came to outpatient department for sudden onset of diminished vision of right eye since one month (CF at 5mts) associated with metamorphasia, OCT of right eye showed macular oedema, retinal thickening .
- **Past history:** Diabetic since 4 years under medication T. Metformin, No H/O Hypertention , he didn't took laser

treatment for another opinion he approached for Ayurvedic treatment.

- **Laboratory investigation:**

FBS:180 mg/dl Date: 15/9/2016

PPBS: 220mg/dl

**Family history:** Nothing specific

**Personal history:** Appetite: Reduced

Bowel: Twice daily

Sleep: Disturbed

Micturation: 5-6 times daily

**General examination:**

**CNS:** consciousness, memory, higher motor mental function intact

**CVS:** NAD

**Examination of the eye:**

Anterior segment: Normal

IOP: Normal

**Fundus examination:** Elevated area on macular region, optic cup and optic disc ratio was normal.

#### Visual acuity

Before treatment	DV	NV	PH
RE	CF-5 mts	N-36	CF-5 mts
LE	6/9	N-8	6/9

DV- Distance vision, NV- Near vision, PH- Pin hole

#### Treatment planned

- *Chitrakadi vati* . 1-1-1 Before food for 3days<sup>[5]</sup>
- *Takradhara*<sup>[6]</sup> with *Musta*, *amalaki*, *punarnava*, *manjishta*, and *haritaki churna* for 7days 2 course
- *Nisha-amalaki churna*. One spoon(5grams) of *choorna* mixed with one glass of hot water, in the morning empty stomach.<sup>[7]</sup>

#### RESULT

After treatment	DV	NV	PH
RE	6/36	N-36	CF-5 mts
LE	6/9	N-8	6/9

Fig.A BEFORE TREATMENT 15 SEPTEMBER 2016

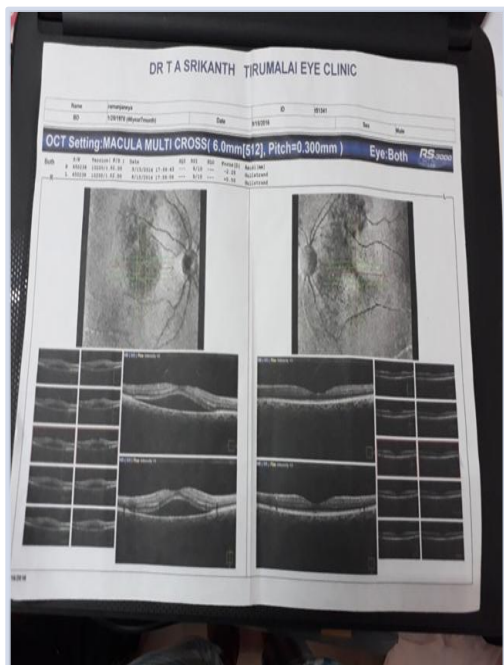


Fig.B AFTER TREATMENT 4 NOVEMBER 2016

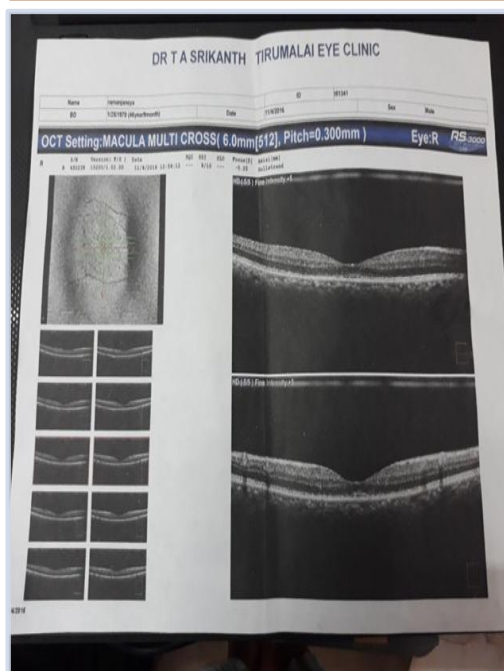


Fig.A shows the fluid accumulation (CSR) in the fovea, and Fig.B shows resolved fluid in the fovea (CSR).

**DISCUSSION:** Line of treatment planned on the basis of vitiation of *Doshas*, here involvement of *Vata* because of *Vimargagamana*, *Pitta* due to vitiation of *Rasavaha* and *Raktavaha srotas* (extravasation of vessels) and *kapha* is due to accumulation of fluid. So *Vatanulomana*, *Rakta prasadan* and *Shophahara* [Anti-inflammatory] are followed.

*Ama pachana* for 3 days

*Takradhara* for 7 days

*Vishrama kala* 15 days

*Takradhara* 7 days

Follow up was done after 15 days.

Initially *Ama pachana* with *Chitrakadi vati* as it contains *chitraka*, *pippali*, *ksharas* (*yava* and *sarja*), *panchalavanas*-absorbes the excess superficial water content<sup>8</sup>, *Trikatu* helps in *Shophahara* as well as *dipana* and *pachana*<sup>9</sup>.

Patient was diabetic so to reduce blood glucose level *Nisha-amalaki choorna*<sup>7</sup> was given along with the treatment.

Then *Takradhara* is planned for 7 days then *vishrama kala* (resting period) for 15 days then *Takra ahara* started for next 7 days. *Takradhara* (pouring of medicated butter milk over forehead) is adopted because *Dhara kalpa* having *Dhatu drudata* (tissue strengthening), *Indriya patava*<sup>6</sup> and procedural effect of *Shiradhara* may act as relaxation response irrespective of *Dravya* (medicine) used. Trauma to the *Marmas* is one of the cause for edema<sup>10</sup> so *Manasika factors* (Stress, Anxiety etc affects *Shira* (head), is one of the *Marma* (vital organ) and it has *Adhishtana* (location) of *Chakshuredriya*, the procedure checks the retinal extravasation and also Anti stress activity was also been noted by many research

workers<sup>11</sup> and stress being one of the major risk factors in central serous retinopathy, *Takra dhara* also strengthens the *Netra*, *Takra dhara* has property *Netra prakasho agada* (doesn't occur any diseases) medium it has *Pancha rasa* except *Lavana rasa*, *Ruksha guna*, *Amla vipaka*, *Ushna veerya* subsides *kapha*, *Madura* and *Amla rasa* subsides *Vata* and also *Takra* contains large amount of lactic acid, is a good vehicle for trans-dermal absorption of drugs. The efficacy of lactic acid contains products is linked to their ability to deliver it to specific skin stratum<sup>11</sup>. other ingredients such as *Musta*, *Manjishta*, *Amalaki* and *Punarnava churna* (powders).

*Musta* is having *Laghu* and *Ruksha* property absorbs all the water content from *Meda* and *Kapha* and anti-inflammatory and antioxidant properties<sup>13</sup>, *Amalaki* has anti-inflammatory and antioxidant properties helps to reduce the oedema<sup>14</sup>, *Punarnava* is also having Anti-inflammatory, Anti-stress and antioxidant activities<sup>15</sup> *Manjishta* has Anti-inflammation effect, Neuroprotective and antioxidant property<sup>16</sup>, the paste of the *Haritaki* effectively reduces the swelling and hasten the healing<sup>17</sup>.

**CONCLUSION:** Even though observation is first line of treatment in central serous retinopathy it takes three to six months to resolve itself in contemporary medicine, but in this case study CSR resolved in one and half month by *Takradhara* as it is found to be stress relieving factor and subside the edema.

#### REFERENCES:

1. Kanski J. Jack and Bowling Brad, Clinical Ophthalmology- A Systemic Approach, Eighth ed; Elsevier: International edition: 2016. pg.624-627. tpg.916.

2. Tarabishy, A.B., Ahn, E., Mandal, B.F and Lowder, C.Y. (2011), central serous retinopathy. Arthritis care Res, 63:1075-1082. doi:10.1002/acr.20485.
3. Sihota Ramanjit, Shiota Radhika Tandon. Parson's Diseases of the Eye. 22<sup>th</sup> ed. New Delhi: Elsevier India Pvt Ltd, Reprint 2007. p.253, tpg 628.
4. Agnivesha. Carakasamhita—Elaborated by Charaka and Dridhabala with the Ayurveda – Dipika commentary by Chakrapanidatta, edited by Vaidya Jadavaji Trikamji Acharya, 5th ed. Varanasi: Chaukhamba Surbharati Prakashan; Reprint 2000. pg16. tpg964.
5. Chitra-Kaviraja shri Govindadassen. Bhisajya rathnavali. Edited by prof. Siddanandana mishra. varanasi. chaukhamba surabharati prakashan. print 2011. pg337-338, tpg.1196.
6. Sahasrayoga Arya simha pal Mahendra, editor. Rao Pandith DV, translator. New Delhi: Kendriya Ayurveda Evam siddha Anusandhana parishad; 1990. pg.621. tpg.518-21
7. Vagbhata. Astanga Hrdayam – with commentaries (sarvanga sundara) of Arunadattas and (Ayurveda rasayana) of Hemadri, edited by Bhisagacharya Harisastri paradakara vaidya, 9<sup>th</sup> ed. Varanasi: Chaukhamba Orientalia; 2005. pg678. tpg956.
8. Dr. Mahesh chand gupta, Dr. Trilok chand – Lavanadi varga – An ayurvedic aspect as well as modern aspect. world journal of pharmacy and pharmaceutical science. vol 6. Issue 2, 2017.
9. Parihar bhupesh kumar et.al. - Role of chitrakadi vati in grahani roga. International Ayurvedic medical journal Issn-2320509. IAMJ: volume 4; Issue 02; January-2016.
10. Madhavakara. Madhava Nidana, Edited by pof. Yadunandana uoadhyaya.

varanasi. chaukhamba prakashan.reprint 2009.part II,pg.27.tpg.606.

11. Priyanka Rani, K.S.Dhiman.A clinical study to evaluate the role of Holistic Ayurveda treatment in pramehaja timira w,s,r background Diabetic retinopathy.Asian Resonance,E;ISSN No.2349-9443,vol-III,issue-III,July-2014.

12. Agnivesha. Carakasamhita— Elaborated by Charaka and Dridhabala with the Ayurveda – Dipika commentary by Chakrapanidatta, edited by Vaidya Jadavaji Trikamji Acharya, 5th ed. Varanasi: Chaukhamba Surbharati Prakashan; Reprint 2000. 738 pp

13. Ramteke Ashok D, Gandhi sonali P,Jivan Thombre B, snehal saurkar. Clinical evaluation of Anti-oxidant activity of Musta with special reference to obesity .Int.J.Ayur.pharma Research.2014;2[2]:83-87.

14. B Antony,M Benny and TNB Kaimal.A pilot clinical study of evaluate the effect of Emblica officinalis extract(AMLAMAX™) on markers of systemic inflammation and Dyslipidemia.Indian journal of clinical Biochemistry,2008/23(4)378-38.

15. Pooja verma A,Lal V.K.Punarnava- A natural Remedy By Ayurveda. International Journal of pharmacy and

pharmaceutical sciences ISSN-0975-1491,vol 6,Issue 8,2014.

16. Verma A,Kumar B,Alam p,singh V and Gupta SK:Rubia cardifolia- A Review on pharmacognosy and phytochemistry.Int J pharm sci Res 2016:7(7):2720-31.doi:10.13040/IJPSR.0975-8232.7(7).2730-31.

17. Prakashchandra Gupta-Biological and pharmacological properties of Terminalia Chebula RETZ-An overview. International Journal of pharmacy and pharmaceutical sciences ISSN-0975-1491.vol 4,supp 13,2012.

---

**Corresponding Author:** Dr.G R Shwetha, Post Graduate Scholar, Department of Shalakyta Tantra, Government Ayurvedic Medical College, Bengaluru, Karnataka,India.  
Email: grshwe20@gmail.com

---

Source of support: Nil

Conflict of interest: None

Declared

**Cite this Article as :**G R Shwetha et al :Ayurvedic Management Of Central Serous Retinopathy - A Case Study: IJAAR VOLUME III ISSUE III JUL-AUG 2017 Page No:573-577