

KSHARSUTRA APPLICATION IN AURICULAR KELOID

A CASE STUDY

¹Sarkar Suman

²Mandal Asim Kumar

³Gupta Mradu

¹Ayurvedic medical officer in Ksharsutra Unit of Post Graduate Ayurvedic Institute, Shyamadas ,Kolkata

²Superintendent of Post Graduate Ayurvedic Institute, Shyamadas ,Kolkata

³Principal of Post Graduate Ayurvedic Institute, Shyamadas ,Kolkata

ABSTRACT :

The Keloid is an overgrowth of fibrous tissue in a scar, occurred in susceptible individuals ¹. It is characterize by excessive collagen following any local trauma, thereby leading to a cosmetically unaesthetic, scar formation and extending well beyond the boundaries of the original wound ². It usually presents as firm nodules, often pruritic and painful, which do not regress spontaneously ³. The condition presents quite a therapeutic challenge due to its frequent invasion to adjacent normal dermis.

Various treatment modalities like pressure therapy, intralesional steroid therapy, cryosurgery, radiation, laser therapy and surgical excision are generally performed for keloids, but there are not so much promising. It was always a challenge to a surgeon. The present paper is the case presentation of an auricular keloid of an adolescent Indian boy by intervention with *Ksharsutra*.

Key words: *Ksharsutra*, Keloid

INTRODUCTION: The term ‘Keloid’ is related to the word “kele” meaning tumor or swelling, owing to its appearance like tumor ¹. Keloid is the formation of a type of scar which, depending on its maturity, is composed mainly of either type III (early) or types I (late) collagen. It was a result of an overgrowth of granulation tissue (collagen type 3) at the site of a healed skin injury which was then slowly replaced by collagen type 1 which are firm, rubbery lesions or shiny, fibrous nodules ³. They are more prone to certain anatomical locations like the anterior chest, back, shoulders, and upper arms, back of the neck, cheeks and ear lobes. They are seen as rubbery or firm nodules or overgrown skin scars, which encourage by infection, wounds and foreign material¹. They are usually asymptomatic, but may present with pain or pruritus. The treatment of keloid is often difficult and

frustrating with unpredictable results and recurrence. There is no comprehensive and definitive treatment such as surgical excision, intradermal steroid instillation, pressure therapy or radiotherapy ⁴. Here one attempt is made to treat the keloid with *ksharsutra*. A young Indian boy, aged 19 years, who had developed right auricular keloid subsequent to trauma, which is successfully managed by *ksharsutra* alone.

CASE REPORT: A 19 year old male patient came to our Shalya OPD of Post Graduate Ayurvedic Institute, Shyamadas, Kolkata. He complains of unsightly appearance of his right ear caused by painless, brown – black coloured oval-shaped growths on his upper right ear lobes (Figures 1).

History revealed that he had recurrent tenia intertigo which he scratch often by his nail, following which a small

nodule has develop adjacent to the area that was behind of upper ear lobe at the junction point where the ear bend to meet the temporal skin, five years back. It increased slowly.

He also received intralesional steroid therapy from the contemporary government hospital, and progression is stop after four injections the keloid reach the present size. Further injection was not given due to complication and advice surgery. He shifted to the ayurvedic treatment for better result.

He also complains of an occasional itching sensation in the affected regions. The growth is circumscribe, ellipsoid in shape, approximately 4 x 2 cm (Figures 1). These have a smooth surface, of the same colour as that of the adjacent skin, and show no signs of inflammation or secondary changes. This bulky peduncle attached by a slender linear stalk to the base of earlobe, which is non-compressible, non-fluctuant, non-tender.

History and clinical features pointed to the obvious diagnosis of right auricular keloid secondary to the trauma. On examination: pulse-76/min, Respiration Rate-20/min, Blood pressure-130/80 other

blood investigation shows within normal limit including blood sugar.

SURGICAL INTERVENTION: After obtaining informed consent from the patient the keloid was planned to be operated by *ksharsutra*. General Pre-operative procedure was maintained. The area was mopped with the disinfect solution. The keloid area carefully monitored and the growth is marked. Local anaesthesia was given by injecting 1 ml of 1% lignocaine hydrochloride beneath the keloid base. The *ksharsutra* was applied in the swelling with the curve cutting needle in the three segments as Goodsall's ligature⁵ (Figures 2a and Figures 2b).

During the follow up of one week the tissue starts to sloughing out the knot had been loose (Figures 3), so again knot was replace by new *ksharsutra* by railroad technique. Two days later the keloid mass is ready to slough out (Figures 4). After four days the *ksharsutra* fall down with the slough (Figures 5). The raw area was then washed with *panchvalkal kashaya* regularly. The wound area diminishes and normal scar visualized within a month (Figures 6). The patient was follow up for one year and showed no evidence of recurrence.

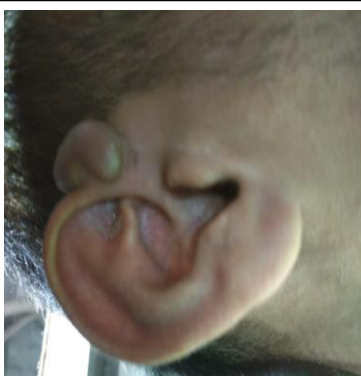


Figure 1

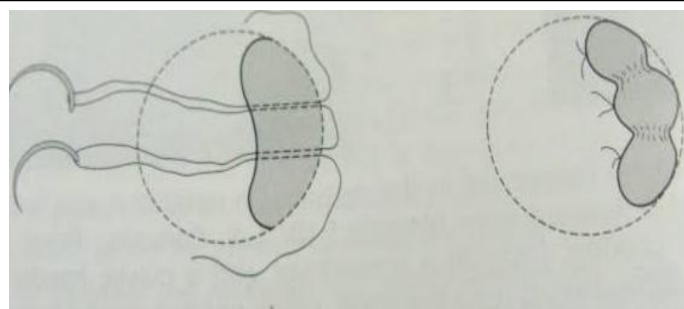


Figure-2a

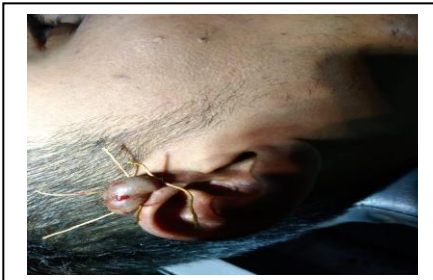

Figure-2b

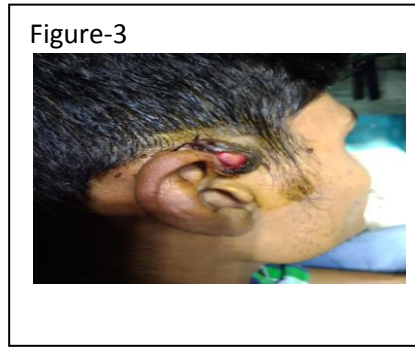

Figure-3

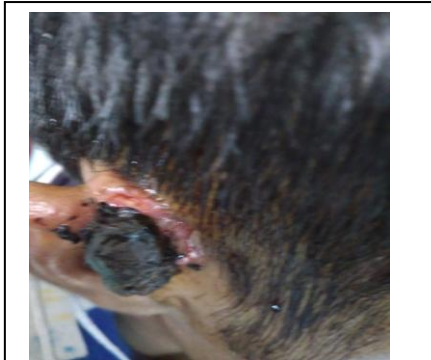

Figure-4

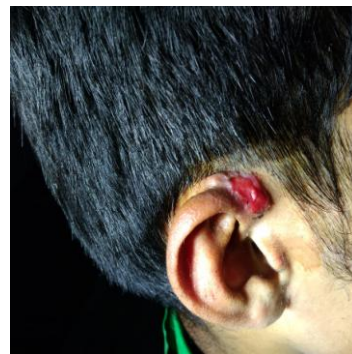

Figure- 5

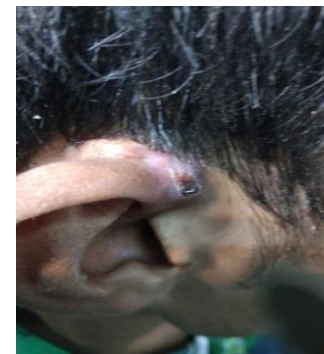

Figure-6

DISCUSSION: A keloid is an excessive proliferation of connective tissue in response to skin trauma and differs from a hypertrophic scar because it extends beyond the limit of the original injury. Operative procedure in keloid is very much controversial and there is more chance of recurrence. Keloid scars are likely to recur if excised, and may be much larger than the original scar⁴. Keloid are different types as per appearance like pedunculated, bulky, guatte, butterfly like etc. All keloid also are not suitable for *ksharsutra*. The pedunculated keloid, which resembles like *arsa* are the best choice for *ksharsutra*.

According to Ācārya Cakrapāni mention preparation of *Ksārsūtra* in *arśa rogādihikar* and it is best in *arsha* and *bhagandar*⁶. The *Ksārsūtra* is prepared by *Snuhī* and *Haridrā* which has *Chedan Bhedan Lekhana*, property as well as healing propriety. The thread is passing the

connective tissue so, no extra *Ksāra* is used. Acharya Charaka had mentioned *arsa* as *adhimamsa* and Acharya Vagbhat mention as *mamsakila* that is muscular projection⁷. *Arsa* generally denote as *guda-arsa* but it can also occur in glans penis, vagina, mouth, nose, ear, eye and anywhere in the skin as it originates from *Twaka*, *Mamsa* and *Meda*⁸. Here *ksharsutra* is applied in keloid which resembles like *arsa*.

Here the base of the keloid was slightly elongated linear type, The linear base is divided in three segments and *ksharsutra* applied and ligated all these segments, from the base. Initially the *ksharsutra* was changed after one week, because the knots are loose. The keloid as a whole sloughed out after four days from the change of *ksharsutra*, The application of *ksharsutra* in keloid may have some different opinion. Further more study needed to establish the efficacy of *ksharsutra* in keloid.

CONCLUSION: Ksharsutra has given some promising result in auricular pedunculated keloid, which resembles like arsa.

REFERENCES:

1. Donald Venes Taber's cyclopedic medical dictionary. 20th Ed Jaypee Brothers Medical Pub. New Delhi, 2005, 1167
2. Hunter J.A.A, Savin J.A. Dahl M.V Clinical Dermatology 3rd Ed A Blackwell Publishing Osney Mead, Oxford UK , 2002: 278
3. Rockwell WB, Cohen IK, Ehrlich HP. Keloids and hypertrophic scars: A comprehensive review. Plast Reconstr Surg 1989; 84:827.
4. McLatchie, Greg; Borley, Neil; Chikwe, Joanna. Oxford Handbook of Clinical Surgery - 3rd Ed Oxford University Press 2007, 15:530
5. Baileys H ; Love Mc. N. Short Practice of Surgery, 25 ed. Norman S. Williams, UK, 2004; 68: 1224
6. Chakrapanidatta, edited by Brahmasankar Mishra 5th ed. Chowkhamba Sanskrita Series Office Chakradutta Chikitsa 45, sloke-148, 1983, 91

7. Vāgbhaṭa ,Aṣṭāṅga Hṛdaya; Hindi commentary- Nirmala by Dr. Brahmananda Tripathi, Chaukhambha Sanskrita Pratisthana .Delhi Nidanāsthāna -7 sloka-1 2003 ,476

8. Agniveśa, Caraka Saṃhitā Hindi commentery carakacandrika-2nd part Dr. Brahmananda Tripathi Chaukhambha Surbharati Prakashan, Varanasi Cikitsāsthāna -15 sloka- 5 & 6 2002; 508 - 509.

Corresponding Author:

Dr. Suman Sarkar, Ayurvedic medical officer in Ksharsutra Unit of Post Graduate Ayurvedic Institute, Shyamadas, Kolkata

Email: sumanayushisarkar@gmail.com

Source of support: Nil

Conflict of interest: None

Declared

Cite this Article as : [Sarkar Suman et al : Ksharsutra Application in Auricular Keloid - A Case Study] www.ijaar.in : IJAAR VOLUME IV ISSUE II MAY - JUNE 2019 Page No: 64-67