

**ABSENCE OF PALMARIS LONGUS AND PSOAS MINOR MUSCLE –
A CASE STUDY**

Kulkarni Swarup Purushottam¹ Patil Sumit Raosaheb² Kalawade Vedashree Abhijit³
¹ Associate Professor, Dept. of Rachana Sharir, ² Associate Professor, Dept. of Panchakarma,
³ Assistant Professor, Dept. of Rognidan & Vikrutivigyan Dr.J.J.Magdum Ayurved Medical college, Jaysingpur, Maharashtra, India

ABSTRACT :

Palmaris longus and Psoas minor muscles are often considered as vestigial muscles in the human body. Palmaris longus is the muscle of upper extremity present in the flexor compartment of the forearm. Psoas minor is the muscle of the posterior abdominal wall. During the dissection of the male cadaver, we found absence of palmaris longus muscle in the left forearm and also psoas minor muscle was absent in the posterior abdominal wall. The other muscles in the forearm were normally located. The arrangement of the other three muscles in the posterior abdominal wall was also normal. The palmaris longus and psoas minor are having less functional importance. There may not be any functional deformity of the upper extremity and the trunk. Palmaris longus is the weak flexor of the wrist and Psoas minor is considered as weak flexor of the trunk. These muscles are inconstant muscles due to its percentage of absence in the human beings. When the palmaris longus muscle is present, its long tendon can be used for the tendon graft surgeries. When psoas minor muscle is present, it also ends in long and flat tendon and it lies anterior to the psoas major muscle entirely within the abdomen. So this is the attempt to throw the light on the information of these muscles.

Keywords : Palmaris longus, Psoas minor, long tendons, vestigial muscles, weak flexors

INTRODUCTION:Palmaris longus is slender fusiform muscle medial to flexor carpi radialis. It springs from the medial epicondyle by the common tendon, from adjacent intermuscular septa and the deep fascia. It converges on a long tendon, which passes anterior (superficial) to the flexor

retinaculum. A few fibres leave the tendon and interweave with the transverse fibres of the retinaculum, most of the tendon passes distally.¹

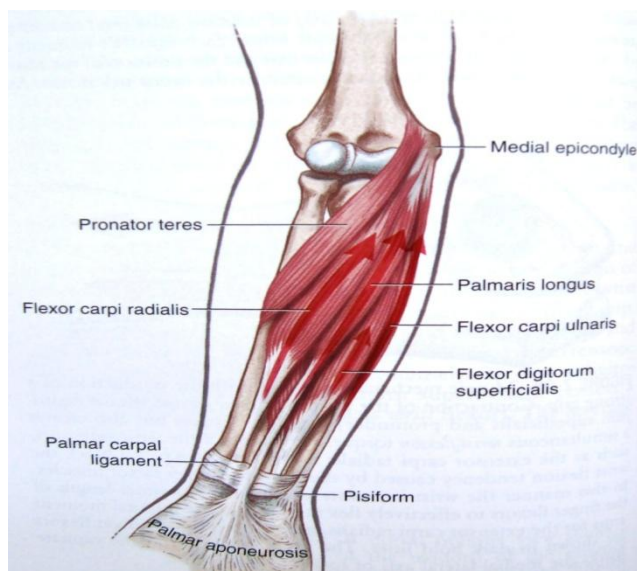


Fig. 1 – Normal Arrangement of the muscles in flexor compartment of forearm

Additional Points :

1. At, the wrist the tendon lies over the median nerve which projects on its lateral side.
2. The palmaris longus muscle is more important morphologically than functionally. It is a degenerating muscle as it has a short muscle belly and a long tendon. It is frequently absent muscle. It is absent in about 10 % subjects.²
3. The palmar apponeurosis represents the distal part of the tendon of

the palmaris longus, another evidence of retrogression of the muscle is Plantaris in the leg.

4. Variations in size, shape and attachments are common.²

Psoas minor is small muscle which lies in front of the psoas major muscle entirely within in the abdomen. It is considered amongst one of the posterior abdominal wall muscle. It also ends in a long, flat tendon.

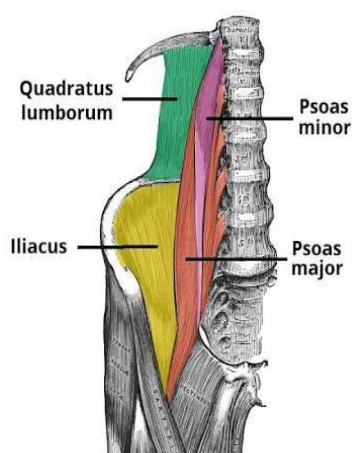


Fig. 2 - Normal Arrangement of the muscles in Posterior abdominal wall

Additional Points:

1. It is frequently absent muscle in about 40% of subjects.¹
2. The short muscle belly and a long tendon.
3. It has an average length of about 24cm, of which about 7.1cm is muscle belly and about 17cm is tendon.^{1,2&3}

Palmaris longus:

Origin & Insertion: It arises from medial epicondyle of the Humerus (common flexor origin) and inserted on the distal half of the flexor retinaculum and at the apex of the palmar apponeurosis.

Vascular Supply: Ulnar artery, superior and inferior ulnar collateral arteries, (variable) anterior and posterior ulnar recurrent arteries, rami from the ends of superficial palmar arch.

Nerve supply : Median nerve (C7& C8)

Actions: Palmaris longus flexes the wrist and makes the palmar apponeurosis tense. It is also suggested to be a phylogenetically degenerate metacarpophalangeal joint flexor. The main function appears to be the anchor for the skin and the fascia of the hand.^{1&2}

Psoas minor :

Origin & Insertion: It arises from the sides of the bodies of vertebrae T12 and L1 and the disc between them and the muscle ends in a long, flat tendon which is inserted into the pectin pubis and the iliopubic eminence, laterally to the iliac fascia.

Vascular Supply: Lumbar arteries, lumbar branch of illiolumbar artery, common iliac artery, sometimes obturator artery and deep circumflex artery.

Nerve supply: A branch from the first lumbar nerve.

Action : Weak flexor of the trunk.^{1&2}

Case study: During the routine dissection for undergraduate students at Dr. J. J. Magdum Ayurved medical College, Jaysingpur, we found absence of Palmaris

longus and psoas minor muscles in left forearm and in the posterior abdominal wall respectively in a male cadaver. Arrangements of other muscles were found normal.

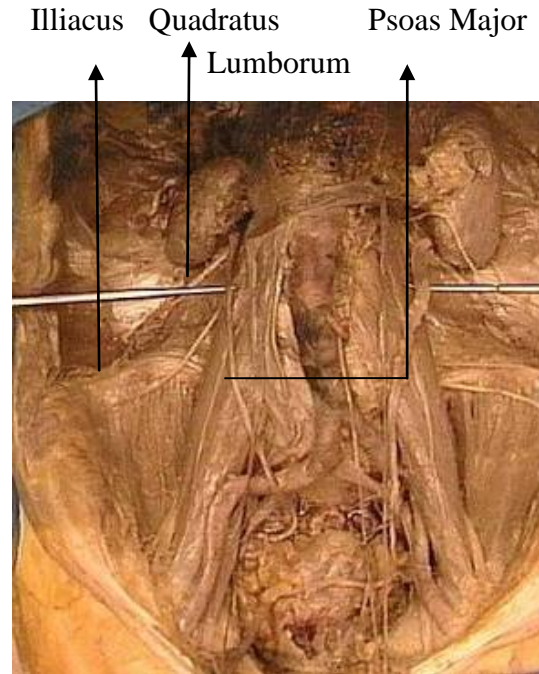


Fig. 3 - Absence of psoas minor Muscle in Cadaver

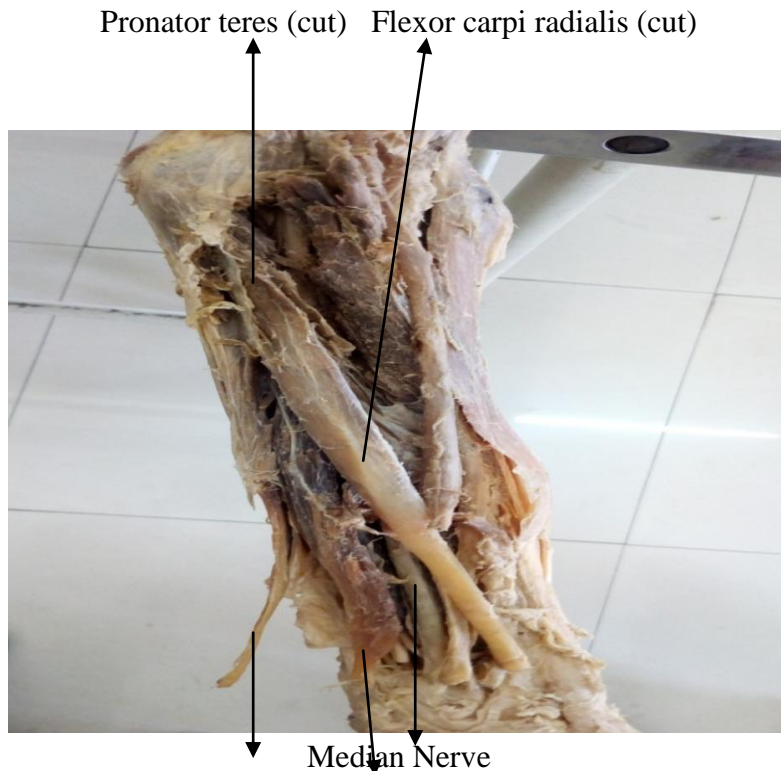


Fig. 4 - Absence of Palmaris longus Muscle in Cadaver

Examination of Palmaris longus muscle

a) Schaeffer's Test – The subject is asked to opposition of the thumb to the little figure with flexion at wrist. Arrow – Palmaris longus tendon.

b) Thompson's Test – Opposed the thumb over clenched fist with flexion at wrist.

Arrow – Palmaris longus tendon.

c) Mishra's Ist Test – Hyperextension of fingers at metacarpophalangeal joint with flexion at wrist. Arrow – Palmaris longus tendon, Arrow head - flexor carpi radialis tendon.

d) Pushpakumar's Test – Extension of index and middle finger with opposed thumb over medial two fingers. Arrow – Palmaris longus tendon.⁴

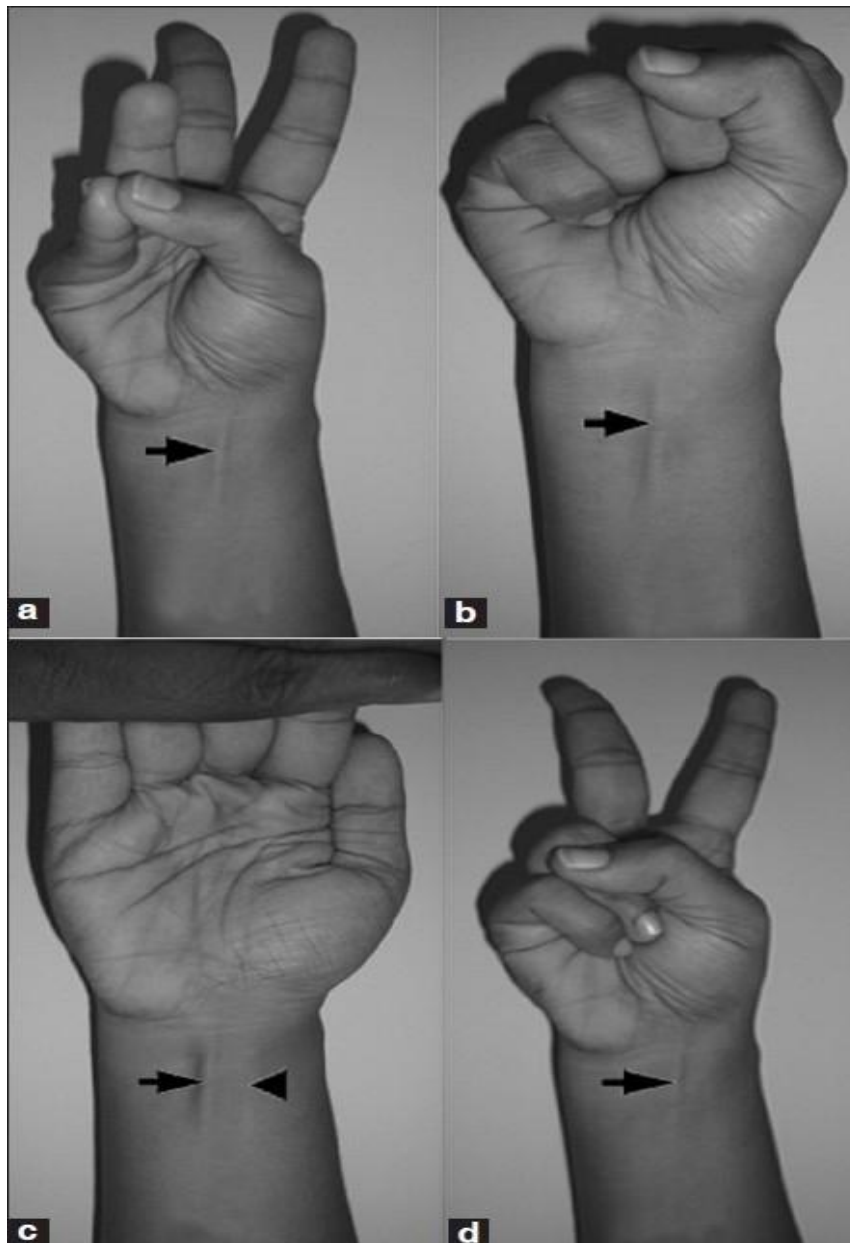


Fig.5 – examination of Palmaris longus muscle by various tests

Psoas sign : The psoas sign is also known as Cope's psoas test or Obraztsova's sign, a medical sign that indicates irritation to the iliopsoas group of hip flexors in the

abdomen and also indicates the inflamed appendix is retrocaecal in orientation. This is done by passively extending the thigh of a subject lying on his side with the knees

extended or asking the subject to actively flex the thigh at the hip. If abdominal pain results then it is a positive psoas sign.⁵

DISCUSSION: Palmaris longus and Psoas minor are weak flexors of the wrist joint and trunk respectively. They are considered functionally negligible. Palmaris longus is absent in about 10 of cases and Psoas minor is absent in about 40% of individuals.^{1&2} The occurrence of agenesis of palmaris longus muscle is reported in some anatomy books. The palmaris longus muscle is a variable muscle. The most common variation is its absence. Several studies have documented the prevalence of absence of the palmaris longus tendon in different ethnic groups. Between 5.5 and 24% of European and North American and 4.6 to 26.6% of Asian populations (Chinese, Japanese, Indian, Turkish and Malaysian) have been reported to lack the palmaris longus tendon.⁶ The palmaris longus muscle is the most popular for use in tendon grafts for the wrist due to the length and diameter of the palmaris longus tendon, and the fact that it can be used without producing any functional deformities.⁷ When a tendon becomes ruptured in the wrist, the palmaris longus tendon may be removed from the flexor retinaculum and grafted to take the place of the ruptured tendon. The tendons most commonly replaced or supplemented by the palmaris longus tendon when ruptured are the long flexors of the fingers and the flexor pollicis longus tendon.⁸ The palmaris longus muscle itself is a weak flexor, and provides no substantial flexing force that would inhibit movement in the wrist if its tendon were cut and moved elsewhere. If the palmaris longus muscle is not available for harvesting in an individual, the anatomically analogous plantaris muscle in

the leg may be taken instead.⁹ Using the patient's own tendon is advantageous, as it does not introduce foreign material into the body. Psoas minor's prevalence of agenesis is also reported as, Russians (Gruber) -- absent in 48%, Alsations (Schwalbe) -- absent in 57%, English (Thomson) -- absent in 59%, Scotsmen (Thomson) -- absent in 63%, Irish (Thomson) -- absent in 66%, Blacks (Loth, Ecstein, Streblow) - - absent in 52.4%, Chinese (Nakano) -- absent in 51.9%¹⁰

CONCLUSION : Palmaris longus and psoas minor are the vestigial muscles in the front of the forearm and in the posterior abdominal wall respectively. These muscles are frequently found absent with rate of 10 and about 40% correspondingly. The tendon of the muscle especially palmaris longus muscle is used for tendon grafts. The tendon is also used in reconstructive surgeries. So, before the surgeries it is necessary for the surgeons to have the information about presence or absence of these muscles. Particularly palmaris longus presence or absence can be confirmed by performing Schaeffer's and other relative tests.

Acknowledgement: This is work was supported by all the teaching and technical staff in the department of Anatomy.

REFERENCES:

- 1) Henry Gray. Gray's Anatomy. 38th edition 1995. Edited by Williams PL, Warwick R et al. Churchill Livingstone, Newyork.
- 2) B.D.Chaurasia, Human Anatomy Vol.1 and 2, CBS publishers & distributors, 4th edition, 2004, New Delhi. Bangalore.
- 3) Mcg Farias (1 Jan. 2012). Morphological and morphometric analysis of Psoas Minor Muscle in cadavers. Research Gate. Retrieved from

<https://www.researchgate.net/publication.280236296> morphological and morphometric analysis of Psoas Minor Muscle in cadavers dated 20/02/2017

4) [https://www.researchgate.net>figure>51452067fig1_a_Schaeffer's test](https://www.researchgate.net>figure>51452067fig1_a_Schaeffer's_test) dated 21/02/2017

5) https://en.wikipedia.org/wiki/Psoas_sign_muscle dated 20/02/2017

6) Kose O, Adanir O, Cirpar M, Kurklu M, Komurcu M (May 2009). "The prevalence of absence of the palmaris longus: a study in Turkish population", Archives of Orthopaedic and Trauma Surgery. 129 (5): 609–11 doi:10.1007/s00402-008-0631-

9. PMID 18418616 dated 20/02/2017

7) Carroll, Will; Gorman, Thomas (June 2009). "Inside Tommy John Surgery". Baseball Prospectus. Retrieved February 2012 dated 21/02/2017

8) Thejodhar P, Potu BK, Vasavi RG (January 2008). "Unusual palmaris longus muscle". Indian Journal of Plastic Surgery. 41 (1): 95–6. doi:10.4103/0970-

0358.41125. PMC 2739544. PMID 19753215 dated 21/02/2017

9) Wheelless, Clifford R (December 2009). "Palmaris Longus Tendon Graft Harvest". Wheelless' Textbook of Orthopaedics. Retrieved February 2012 dated 21/02/2017

10) Mori, M. (1964) Statistics on the Musculature of the Japanese. Okajimas' Fol. Anat. Jap. 40:195-300 dated 21/02/2017

Corresponding Author:

Dr. Swarup P. Kulkarni, Associate Professor, Dept. of Rachana Sharir, Dr.J.J.Magdum Ayurved Medical college, Jaysingpur, Maharashtra, India
Email: drswarupkulkarni57@yahoo.com.au

Cite this Article as: Kulkarni Swarup Purushottam et al : Absence of Palmaris Longus and Psoas Minor Muscle : A Case Study