

EFFECTIVE AYURVEDIC TREATMENT ON LEUCODERMA IN EARLY STAGE- A CASE REPORT

¹Shreya Umesh Sawant,

²Jayant Subhash Hartalkar

¹Associate Professor of Rachana Sharira, Dr. D. Y. Patil School of Ayurved , Nerul, Navi Mumbai, India

²Assistant Professor of Rachana Sharira, Dr. D. Y. Patil School of Ayurved , Nerul, Navi Mumbai, India

ABSTRACT :

Leucoderma appears to affect at least 1% to 2% of population, it is usually harmless but for cosmetic reasons, it is nuisance to those who have it. It is characterized by loss of pigmentation of skin. According to Ayurveda, this condition can be treated as Shvitra which gives effective results without any side effect. A patient of Leucoderma treated as a Shvitra with traditional Ayurvedic treatment is presented in this case study.

Key words: Leucoderma, Shvitra, Ayurvedic treatment

INTRODUCTION: Leucoderma is a cutaneous condition, an acquired condition with localized loss of pigmentation of the skin.¹ It appears to affect at least 1% to 2% of the population, irrespective of sex, race, or age. It is largely a cosmetic problem, and is neither infectious nor contagious. The change in appearance caused by Leucoderma can affect a person's emotional and psychological well-being and may create difficulty in getting or keeping a job. People with this disorder can experience emotional stress. It has become a marked social stigma in countries such as India, where opportunities for social advancement or marriage among affected individuals are severely limited even today. Various modern treatments actually with suppressive medicines like steroids complicate Leucoderma and make it partially untreatable . With long-term use of topical steroid the skin may develop permanent stretch marks (striae), bruising, discolouration, or thin spidery blood vessels (telangiectasias). Topical steroids may trigger or worsen other skin disorders such as acne, rosacea and perioral

dermatitis.² On the basis of clinical features, Leucoderma can be considered as *Shvitra* mentioned in Ayurved. It is considered under Kushta. It is caused by vitiation of *Tri Dosha* and stays in *Rakta Mansa Meda Dhadhu*.

Ayurvedic treatment can manage and treat Leucoderma successfully in early stage. Leucoderma treatment is possible though Ayurveda but it needs special care. If a patient with recent onset of Leucoderma starts Ayurvedic treatment then there are more than 99% chances of its cure. A known case of Leucoderma was treated as a *Shvitra* mentioned in *Samhitas* with traditional Ayurvedic method is presented in this study.

MATERIAL:

A Female patient of Leucoderma. Age: 38Yrs

Modern Medicines taken for 1yr for the same. Due to No significant results and side effects such as Hyperacidity and constipation, patient came for Ayurvedic treatment in clinic. (Kamothe ,Navi Mumbai)

METHODS: C/O : white colored patches on back of neck ,back region since 1 yr, itching .

H/O: Acidity, Constipation since 6 mnths.

No H/O OF B.P., Diabetes

Menstrual History: Regular

Obs /H: 2 male children L.S.C.S

No H/O Abortions

O/E : : white colored patches on back of neck ,back region

P/A: SOFT Tongue: Coated

Pulse: 82/min, B.P.: 130/90 mm of Hg

No specific investigations.

Rx For 15 days

1. Arogyavardhini 1 tab TDS after food.
2. khadiradi kashaya ³2TSF + 4 Tsf worm water BD after food.
3. Gandharva haritaki 2 tab at bed time with warm water
4. Jalauka application on patches once in week.
5. Bakuchi oil application daily on patches and advised to take morning sunlight for 10-15 min.

Patient is advised to avoid oily, spicy and sour foods, non veg.

Follow up after 15 days :

O/E: Patches turn in pink colour,

Itching - Reduced

Acidity – Reduced

No Constipation

From above symptoms,

Treatment is changed - for 30 days,

1. Swayambhu guggul ⁴1 tab TDS after food.

2. Gandhak Rasayan 1 tab TDS after food.

3. Mahatikta ghrit 1 tsf in mornig with warm water

4. Gandhrva haritaki 2 tab at bed time with warm water

5. Jalauka application on patches in a week

Follow up after 30 days :

O/E: Patches with normal skin colour

No itching on patches

No Acidity

No Constipation

Same Treatment is continued for next 15 days.

RESULTS AND OBSERVATIONS:

Before Treatment: white colored patches on back of neck ,back region with itching on patches, Acidity and Constipation

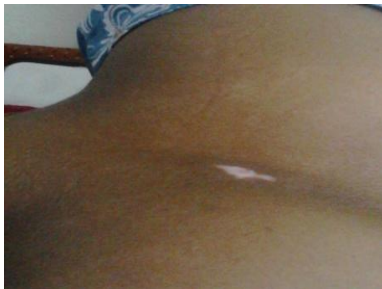
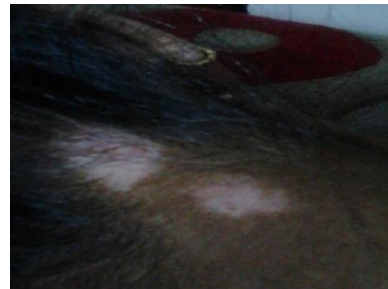
Fig 1 . Before treatment patch on (a) back



(b) back of neck

After 15 days – Due to medicines,

Acidity reduced and constipation is completely cured

Due to **Jalauka application** ,colour of patches turned into pink colour

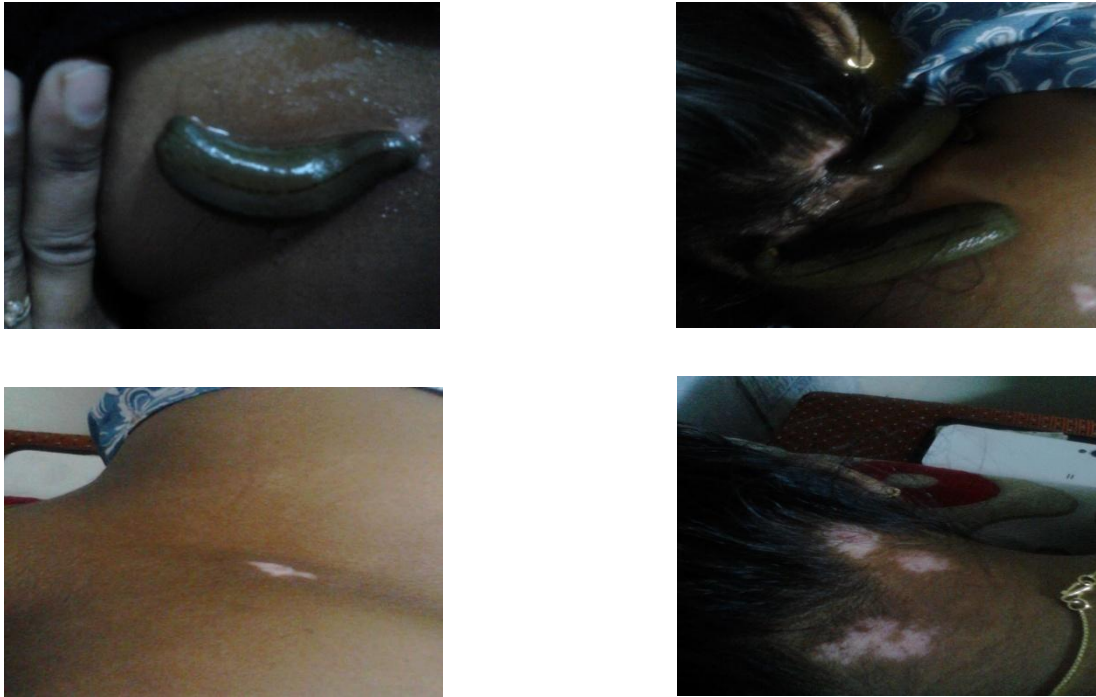


Figure 2. pink colour patches after Jalauka application
After 30 days- Patches with normal skin colour



Figure 3: normal skin skin colour on patches

DISCUSSION:

Patient had acidity and constipation before treatment, so for *deepan and pachana* *Arogyavardhini* is used in first 15 days.⁵

As *shvitra* is produced by vitiation of *Tridosha and Rakta Dhatu*, Hence *Rakta prasadak*, *raktashodhak* medicines are given.⁶

Virechan is the advised for *Shvitra*, so *Gandhrva haritaki* is used as a *nitya virechana*.⁷

Swayambhu guggul and Bakuchi are *shvitrhar*, so *bakuchi oil* application will provide normal colour to *twacha* by correcting function of *Ranjak Pitta*.⁸

Jalauka application helps in removing local *Rakta dushti* and correcting function of *Ranjak pitta*.⁹

All medicines are used which especially act on *Rakta Dhatu*.⁷ Such as *Gandhak rasayan*⁷ is used for *Raktashodhan*.¹⁰

CONCLUSION: There are very good medicines available for the skin diseases in Ayurved which gives better results than modern medicines. Also, modern medicines may develop some side effects which are hazardous.

Ayurvedic treatment is the safest and successful treatment offered till date which is result oriented and is side effect free in challenging condition like Leucoderma in early stage. Ayurveda is considered such treatment as it's an herb based treatment and known to be work on internal reasons to rectify the problem from roots.

Leucoderma can be considered as *Shvitra* mentioned in *Samhitas* and can be successfully treated by using *Raktashodhk*, *Raktaprasadak* *Dravyas* and *Jalauka* application.

REFERENCES:

1. <https://en.wikipedia.org/wiki/Leukoderm>
a date of assessment : 27 May 2015
2. noblevitiligoclinic.com/vitiligo.html
date of assessment: 27 May 2015
3. Yogratanakar,Uttarkhanda by Vaidya Lakshmipati Sastri,Chaukhambha Prakashan,Varanasi,edition :2010,page no. 233, Shvitraadhikar/2
4. Bhavprakash Part II , by Shri Brahma Sankara Mishra,Chaukhambha Sanskrit Sansthan,Varanasi,8th edition :2003, page no.535,54/67.
5. Rasaratna Samuchchaya by Kaviraj Shri Ambikadatta Sastri,Chaukhambha Amarbharati Prakashan,Varanasi,9th edition :1995, 91page no.400,20/91.
6. Ashtang Hridaya edited by Ganesh Garde,reprint ed.Anamol Prakashan 2003, Pageno.207, Nidan sthana chapter 14, verse no.37.
7. Ashtang Hridaya edited by Ganesh Garde,reprint ed.Anamol Prakashan 2003,

Pageno.322, Chikitsa sthana chapter 20, verse no.2

8. Bhavaprakash Nighantu by Dr.G.S.Pandey,Chaukhambha Bharati Academy,Varanasi,revsed edition-2010,page no.119.

9. Ashtang Hridaya edited by Ganesh Garde,reprint ed.Anamol Prakashan 2003, Page

no.323, Chikitsa sthana chapter 20, verse no.18

10. Yogratanakar,Uttarkhanda, by Vaidya Lakshmipati Sastri,Chaukhambha Prakashan,Varanasi,edition :2010,page no. 501, Rasayanadhikar/3.

Corresponding Author : Dr. Shreya Umesh Sawant, Associate Professor of Rachana Sharira, Dr. D. Y. Patil School of Ayurved, Nerul, Navi Mumbai, India
Email: sawant_ujjwala@yahoo.com

ACKNOWLEDGEMENT:

I acknowledge all colleagues, parent and colleagues who helped a lot in making this article very effective in very short time. Acknowledge co-author for his valuable Contribution.