

SURGICAL ANATOMY OF KURPARA MARMA WITH SPECIAL REFERENCE TO ELBOW JOINT INJURY

¹Geethakumar,

¹Assistant Professor, Department of Rachana Shareera Sri Jayendra Saraswathy Ayurveda College, Chennai

ABSTRACT :

Marma is constituted by confluence of *Mamsa* (muscle), *Sira* (vessels), *Snayu* (nerve, tendon, ligament), *Asthi*(bone), *snadhi* (joints). This five tissue participate to play vital role in prognosis of traumatic result. *kurpara marma* is one of the *Vaikalyakara marma* (loss of function). *Kurpara marma* or *kurpara sandhi marma* includes the proximal radioulnar and the joint between humerus, and radioulnar. An injury to this *marma* causes deformity, pain and swelling. The articulation of elbow joint occurs between the trochlea and capitulum of humerus and trochlear notch of the ulna and head of radius. The elbow is capable of simple hinge movement of flexion and extension injury oriented deformity at elbow joint. Such injuries causes dislocation, subluxation, sprain, instability, leading to severe pain stiffness and deformity. Injuries can be avoided by certain preventive measures.

Key words: *kurpara marma*, *Vaikalyakara marma*, elbow joint, injury.

INTRODUCTION:

Marma : “*mārayati iti marma*” (*Dalhana*), *api ca maraṇakāritvāt marma* |. According to *Dalhana*, *Marma* is that spot on the body surface where if any injury or trauma is made causes death. There are 107 *marma* on the human body surface. These *Marmas* are classified according to anatomical structure as *Mamsa*(muscle), *Sira*,(vessels) *Snayu* (ligament, tendon, nerves,) *Asthi*(bone) & *Sandhi*(joint) and according to prognosis *Sadyopranahar marma*,(immediate death), *Kalantara pranahara* (death after some time), *Vaikalyakar marma*(deformity), *Visalyaghna* (death due to removal of foreign body) and *Rujakara*(painful) . *Kurpara marma* is present in the upper limb joining place of arm and forearm. If it gets injured there will be disability. There are many anatomical and surgical structures related with *kurpara marma* which can be compared with elbow joint. Injury of which leads disability or loss of function. Elbow joint is synovial joint present

between lower end of humerus and the upper end of radius and ulna. It is associated with many complications following injury or trauma.

***Kurpara marma* :** *Prakoṣṭapraṇāḍayoḥ sandhāne kūrpara nāma, tatra kuṇiḥ*¹

kurpara marma situated in the upper limb, it is 2 in nos, structurally it is of *sandhi marma*, prognostically it is of *vaikalya kara marma* , it is present inbetween *prakoshta*,(humerus) *prakanda* (radius, and ulna) *asthi* . Measurement of the *marma* is 3 *angula.*, injury to this *marma* leads to dangling of hand (hanging or swinging loosely), deformity of upper limb. Stiffness or restricted movement of upper limb.

***Vaikalya kara marma*:** There are 44 *vaikalya kara mara* present in body, which produce *vaiklaytwam* (disability). *Kurpara marma* is one of the *vaikalyakara marma* present in the both upper extremity. *Marma* which are producing disability due to presence of *soma* (water) *mahabuta*, *soma* (water) due to firmness and coldness

sustain life². If *vaikalya kara marma* is getting injured, the part of body becomes disabled, but if treated by efficient physician it becomes active.³

Patient can be saved from injury or trauma of little intensity but the patient becomes permanently handicapped or develops disability to lead passive life.

Viswachi roga is the one of the *vata vyadhi*, which affects the ligaments or nerves of the upper arm, makes the arm inability to do the function. The upper arm become *karma kshaya kari*,⁴

As per description of location and injurious effects *Kurpara marma* may be correlated with elbow joint.

Elbow joint:

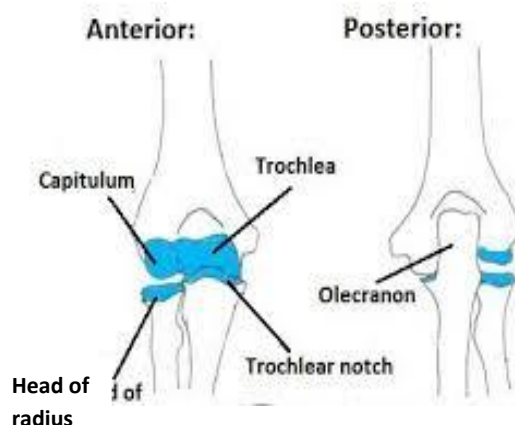


Figure No.1 – Anatomy of elbow joint

(<http://teachmeanatomy.info/wp-content/uploads/Articulations-of-the-Elbow-Joint.jpg>)

Elbow joint is a synovial joint of the hinge variety between the lower end of humerus and the upper end of radius and ulna. Upper surface of the head of radius articulate with capitulum of humerus and trochlear notch of the ulna articulates with trochlea of the humerus. The elbow joint is continuous with the superior radio ulnar joint. In full flexion the fossae present immediately above the capitulum and trochees receive the head of radius and coronoid process of the ulna, and in full extension, a deep fossa which present posterior receives the olecranon. The transverse axis of elbow joint is directed medially downward so in extended forearm it makes carrying angle⁵.

The upper surface of the cylindrical head of the radius is spherically concave to fit the capitulum. The upper end of the ulna shows the deep trochlear notch. A curved ridge joins the the prominence of coronoid

process and olecranon the ridge fits the groove in the trochlea of the humerus. The obliquity of the shaft of the ulna to this ridge accounts for most of the carrying angle at the elbow. There are commonly two separate articular surface in the trochlear notch, one on the olecranon, and the other coronoid process.

Capsular ligament: superiorly it is attached to the humerus at the margins of the lower rounded ends of the articular surfaces of capitulum and trochlea, radial fossae, the coronoid fossae, and the olecranon fossa are intracapsular, Inferomedially, it is attached with margins of trochlear notch of the ulna except laterally, inferolaterally to the annular ligament of the superior radio ulnar joint. Synovial membrane lines inner surface of capsular ligament and above named fossae.

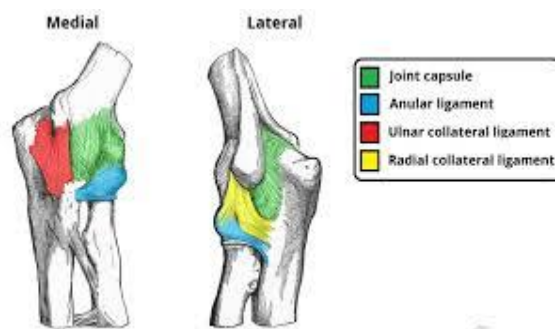


Figure No.2 - Ligaments of elbow joint

(<http://teachmeanatomy.info/wp-content/uploads/Ligaments-of-the-Elbow-Joint-Lateral-and-Medial-Aspect-1024x564.jpg>)

The capsule and annular ligament are lined with synovial membrane, which is attached to the articular margins of three bones. The synovial membrane, thus floors in the coronoid and olecranon fossae on the lower end of the humerus, and bridges the gap between the radial notch of the ulna and neck of the radius. The quadrate ligament prevents herniation of the synovial membrane between the anterior and posterior free edges of the annular ligament.

The ulnar collateral ligament of the elbow joint is triangular and consists of three bands. The anterior band is the strongest. It passes from the medial epicondyle of the humerus to a small tubercle on the medial border of the coronoid process. The posterior band joins the sublime tubercle and

the medial border of the olecranon. A middle band connects these two and lies more deeply, it lodges ulnar nerve on its way from the arm to the forearm.

Radial collateral ligament is single collateral ligament is a single flattened band attached to the humerus below the common extensor origin; it fuses with the annular ligament of the head of the radius. The anterior and posterior ligaments are merely thickened parts of the capsule.

The annular ligament are attached to the margins of the radial notch of the ulna and clasps the head and neck of the radius in the proximal radio ulnar joint. It has no attachment to the radius which remains free to rotate to the annular ligament.⁶

Nerve supply: Musculocutaneous nerve, Median nerve, Ulnar nerve, Radial nerve.

MOVEMENTS

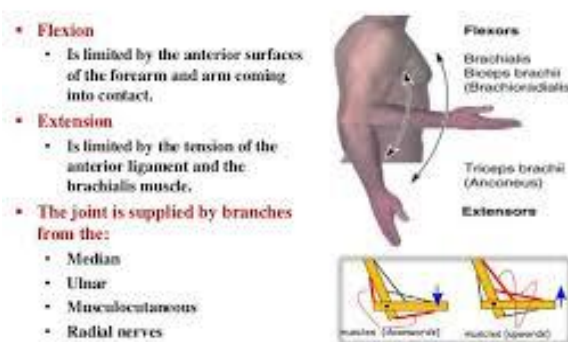


Figure No.3 - Movements of elbow joint

(<http://image.slidesharecdn.com/armelbowjoint-150117013910-conversion-gate01/95/arm-elbow-joint-24-638.jpg?cb=1449435669>)

Movement: The elbow joint is capable of flexion and extension. Flexion is performed by brachialis, biceps brachii, brachioradialis, and pronator teres muscles, it is limited by anterior surface of forearm and arm. Extension is performed by the triceps and anconeus muscles, and it is limited by tension of anterior ligament and brachialis muscle. From the extended position the range of flexion is about 140degree, the extended ulna makes with the humerus an angle of 170degree, this is called carrying angle.

A pathological increase in this valgus angle may gradually stretch the ulnar nerve behind the medial epicondyle and cause an ulnar nerve palsy. During pronation, supination of the forearm there is some rocking movement of the ulna on the trochlea, in extension the tip of the olecranon lies with the humeral epicondyles, but in full flexion these three bony points make an equilateral triangle.⁷

Stability of elbow joint: The elbow joint is stable because of the wrench shaped articular surface of the olecranon and the pulley shaped trochlea of the humerus. it is also has strong medial and lateral ligament.⁸

Surgical approach: The commonest approaches for surgery are from the sides.

Medially the ulnar nerve is displaced backward and the common flexor origin detached to expose the capsule, while on the lateral side the common extensor origin is similarly detached. on this side the capsule incision must not extend lower than the level of the radius to avoid damage to the posterior interosseous nerve as it winds round the shaft within the supinator.

For aspiration or injection the needle is inserted on the posterolateral side above the head of the radius, with the elbow at a right angle, the medial side is avoided because of the ulnar nerves.⁹

Clinical notes: Elbow joint is commonly injured joint in childhood. The problem affecting the joint could be intra articular or extra articular. TB arthritis, rheumatoid arthritis is some of the common intra articular problems. While tennis elbow, golfers elbow, students elbow are some of the extra articular problems of elbow.

Supra condylar fracture dislocation of elbow, in fracture head of radius are some of the common elbow injuries.

Tennis elbow: is caused by partial tearing or degeneration of the origin of the superficial extensor muscles from the lateral epicondyle of the humerus.

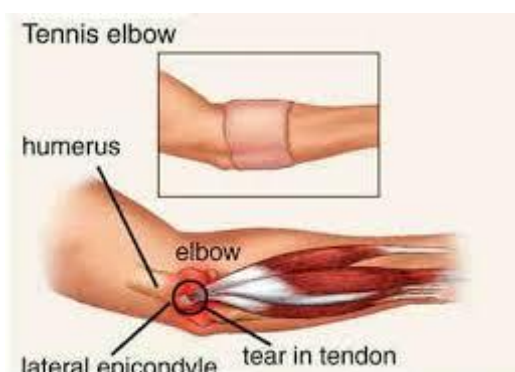

Figure No. 4 - Tennis Elbow

(<http://3.bp.blogspot.com/>-

N6eStZrzmOM/VMhzjDI7zhi/AAAAAAAAABo/hPjFQGWLdCk/s1600/tenniselbow.jpg)

It is characterised by pain and tenderness of the lateral epicondyle of the humerus., with pain radiating down the lateral side of the forearm, it is common in tennis players violinists, and housewives.¹⁰

Dislocation of the elbow joint: Elbow dislocations are common and most are posterior. Posterior dislocation usually follows falling on the outstretched hand. posterior dislocation is common in children because the parts of the bones that stabilize the joint are incompletely developed. Avulsion of the epiphysis of the medial epicondyle is common in child hood

because medial ligament is much stronger than the bond of union between epiphysis and the diaphysis.

Arthrocentesis of the elbow joint: The anterior and posterior walls of the capsule are weak, and when the joint is distended with fluid the posterior aspect of joint become swollen. Aspiration of joint fluid can easily be performed through the back of the joint on either side of the olecranon process.¹¹

Golfers elbow: It is a tendinopathy of the insertion of the flexors of the fingers and pronators.

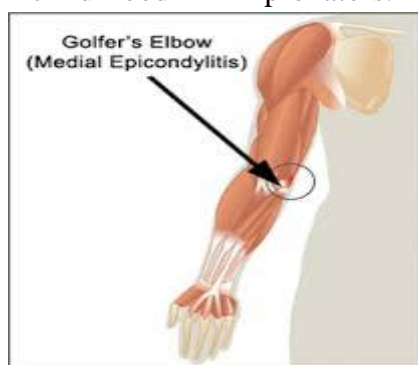


Figure No. 5 - Golfer's elbow

(<http://i0.wp.com/www.orthopaedics.com.sg/wp/wp-content/uploads/2011/07/golfer-elbow.gif?resize=252%2C300>)

Golfers elbow very similar to the tennis elbow but occurs at the medial side of the elbow, where the pronator teres and the flexors of the wrist are originates . Tensing of these muscles by resisted wrist and finger flexion in pronation will provoke pain.¹²

Student elbow: (miners) characterized by effusion in to the bursa over the subcuta

neous posterior surface of olecranon process. It occurs due to repeated minor injuries as in students who tend to keep their elbow repeatedly over the table for longer periods during writing and reading. Presence as a painful swelling over the tip of olecranon.¹³



Injury to elbow joint : Figure No. 6-Damage to the ulnar nerve with elbow joint injuries.

The close relationship of the ulnar nerve to the medial side of the joint often results in its becoming damaged in dislocation of the joint or in fracture dislocations in this region. The nerve lesion can occur at the time of injury or weeks, months, year later. The nerve can be involved in scar tissue formation or can become stretched owing

to lateral deviation of the forearm in a badly reduced supracondylar fracture of the humerus. During movements of the elbow joint, the continued friction between the medial epicondyle and the stretched ulnar nerve eventually results in ulnar palsy.¹⁴

Radiology of the elbow region after injury:

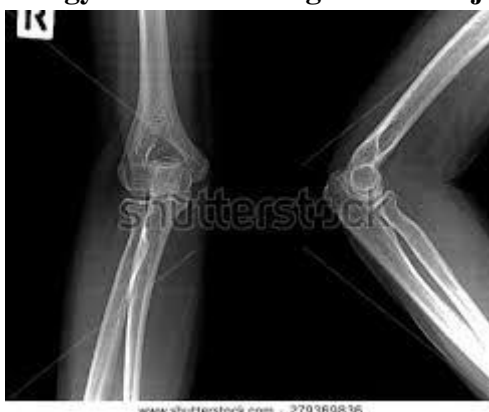

Figure No. 7

(http://image.shutterstock.com/display_pic_with_logo/2048756/279369836/stock-photo-elbow-x-rays-elbow-joint-antero-posterior-on-a-black-background-279369836.jpg)

In examining lateral radiograph of the elbow region it is important to remember that the lower end of the humerus is normally angulated forward to 45° on the shaft, when examining a patient the physician should see that the medial epicondyle, in the anatomical position, is directed medially and posteriorly and faces in the same direction as the head of humerus.¹⁵

Musculocutaneous nerve:

Musculo cutaneous nerve rarely injured because of the protected position beneath the biceps brachii muscle. If it is injured high up in the arm, the biceps coracobrachialis are paralysed and the brachialis muscle is weakened. a continuation of the musculocutaneous nerve beyond the cubital fossa, then the nerve is called lateral cutaneous nerve. Wounds or cuts of the forearm can sever the lateral cutaneous nerve of the forearm, resulting

sensory loss along the lateral side of the forearm. There is also sensory loss along the lateral side of the forearm. Wounds or cuts of the forearm can sever the lateral cutaneous nerve of the forearm, a continuation of the musculocutaneous nerve beyond the cubital fossa, resulting sensory loss along the lateral side of the forearm.

Median nerve: the median nerve is injured occasionally in the elbow region in supracondylar fracture of the humerus, clinical findings are below, the muscles supplied by it in cubital fossa, forearm, and hands are paralysed, there will be motor loss of four and half flexors of forearm, two pronators of forearm leading to 'pointing index fingers' of thenar eminence, muscles and 1st and 2nd lumbricals. These muscles are responsible for gross movement.

Sensory: Skin sensation is lost on the lateral half or less of the palm of the hand and the palmar aspect of the lateral three and half fingers. Sensory loss also occurs on the skin of the distal part of the dorsal surfaces of the lateral three and half fingers. The area of total anesthesia is considerably less because of the overlap of adjacent nerves.

Vasomotor changes : The skin area involved in sensory loss are warmer and drier than normal because of the arteriolar dilatation and absence of sweating resulting from loss of sympathetic control.

Tropic changes:In long standing cases, changes are found in the hand and fingers .The skin becomes dry and scaly , the nails cracks easily and atrophy of the pulp of the fingers is present.

Ulnar nerve injuries at the elbow: If ulnar nerve is injured at the elbow, medial half of flexor digitorum profundus gets paralysed and causes claw hand wasting of paralysed muscles, flattening hypothenar eminence and loss of convex curve to the medial border of hand.¹⁶

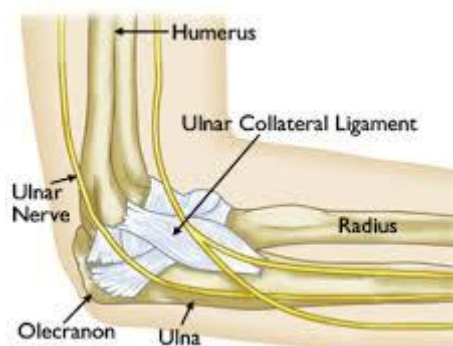


Figure No. 8

(<http://orthoinfo.aaos.org/figures/A00646F01.jpg>)

Sensory: Loss of skin sensation will be observed over the anterior and posterior surfaces of the medial third of the hand and medial one and half fingers.

Vasomotor changes: The skin areas involved in sensory loss are warmer and drier than normal because of the arteriolar dilatation and absence of sweating resulting from loss of sympathetic control.

Treatment of elbow injuries: It consists of rest, holding cold compress, non-steroidal anti-inflammatory drugs, local anesthetic, and steroid injection, and physiotherapy. Tennis player exercises, light pocket, smaller grip, elbow support. Chronic cases require surgery.¹⁷

In Ayurvedic perspective injury increases *vata*, so, the treatment should consist of *vatha hara*, drugs in the treatment. They

are *lepam* with *vata hara sothahara* and *raktaprasadaka dravyas*, *pichu* with *vatha hara thilams*, and *Dhara* with *vatha hara tailas*.¹⁸

General preventive measures of elbow:¹⁹

1. Don't carry objects that are too heavy
2. Stretch before and after physical exercise.
3. Do stretching and range-of-motion exercise with finger and wrist to prevent stiffening of the tendon of the elbow.
4. Gently bend, straighten, and rotate your wrist., if pain is there then stop the exercise.
5. To prevent strain of muscles use the correct movement or positions during activities.

6. Avoid over use of arm, doing repeated movement, which will cause injury to the bursa.
7. Wear seat belt while travelling in a motor vehicle.
8. Wear protective gear during sports or recreation such as roller-skating or soccer.
9. Supportive splints reduce the risk of injury.
10. Wear protective clothing to protect sports injury.

CONCLUSION: elbow joint is a compound para condylar joint as the lower end of humerus articulate with the radius and ulna, it is a hinge joint allowing only flexion and extension, arc of 150degree. The three component of elbow is humeroulnar, humero radial and proximal radio ulnar joints share the same joint capsule. Capsule is re enforced laterally, by the radial collateral ligament, medially by ulnar collateral ligament, the annular ligaments holds radius in position. . The stability of joint produced by the wrench shaped articular surface of the olecranon and the pulley shaped trochlea of the humerus . It also has strong medial and lateral ligament. All this anatomical structure makes the joint respond differently to trauma, exercise and massage etc., In spite of this anatomical structure it is vulnerable to the traumatic effect of these region produce pain and inflammation and loss of function. Blunt trauma produces permanent disability. Foreign body in bone produces many type of pain and inflammation, if foreign body present in the joint produces loss of function

In ayurvedic point of view *kurpara marma* abhigataja leads to **deformity of elbow**, produces swinging of arm, stiffness of arm , painful restricted *movement of upper limb. Because of this disability our*

Acharyas have mentions that kurpara marma is vaikalyakara marma. In day to day life , various sports activity, improper use of forearm and arm , any nerve injury, muscle weaknes, will hamper the function of elbow joint, so we have to prevent the joint from injury and proper strengthening should be given for proper functioning to avoid vaiklalyatha.

ACKNOWLEDGEMENT: I thank Sri Chandrasekrandra Viswa Maha Vidyalaya, Enathur kanchipuram for providing support for publication of the article

REFERENCES:

1. Priyavat Sharma , *Susrutha samhitha , sharirasthanana* 6/24 published by Choukhambha visvabharati Oriental publishers & distributors.varanasi.reprint 2005.
2. Prof. D.G Thatte, *Susrutha samhitha shareerasthanana* 6/12-13 published by Choukhambha publishers, second edition 2005.
3. Prof. D.G Thatte, *Susrutha samhitha shareerasthanana* 6/12-13 published by Choukhambha publishers, second edition 2005.
4. Kaviraj Ambikadatta Sastri, *Ayurveda tatwa dipika,Susrutha samhitha Nidana sthana*, chapter 1/75, published by Choukhamba samasritha samsthana, Varanasi,Reprint 2007.
5. B.D Chaurasia, Human anatomy. CBS publishers ,4th edition , pageno-149
6. R.M.H. MCMiNN, Last's Anatomy Regional and Applied published by CHURCHILL LIVINGSTONE Medical Division of Pearson professional Limited , International student Edition of ninth edition Reprinted 1997. Page no 83.
7. R.M.H. MCMiNN, Last's Anatomy Regional and Applied published by CHURCHILL LIVINGSTONE Medical Division of Pearson professional Limited ,

International student Edition of ninth edition Reprinted 1997. Page no 85.

8. John Ebnezar- Text book of Arthopaedics, published by Jaypee brothers, Medical publishers New Delhi Reprinted 2003

9. R.M.H. MCMiNN, Last's Anatomy Regional and Applied published by CHURCHILL LIVINGSTONE Medical Division of Pearson professional Limited , International student Edition of ninth edition Reprinted 1997. Page no 85.

10. Richard S. Snell, clinical Anatomy published by Lippincott Williams & Wilkins 7th edition chapter 9 page no533

11. Richard S. Snell, clinical Anatomy published by Lippincott Williams & Wilkins 7th edition chapter 9 page no551

12. John Ebnezar- Text book of Arthopaedics, published by Jaypee brothers, Medical publishers New Delhi Reprinted 2003 page no 195

13. B.D Chaurasia, Human anatomy. CBS publishers ,4th edition , pageno-.195

14. Richard S. Snell, clinical Anatomy published by Lippincott Williams & Wilkins 7th edition chapter 9 page no551

15. Richard S. Snell, clinical Anatomy published by Lippincott Williams & Wilkins 7th edition chapter9 page no551

16. Richard S. Snell, clinical Anatomy published by Lippincott Williams & Wilkins 7th edition chapter 9 page no582.

17. John Ebnezar- Text book of Arthopaedics, published by Jaypee brothers, Medical publishers New Delhi Reprinted 2003 Page no 184.

18. Priyavat Sharma, *Susrutha samhitha, chikitsasthana* 2nd chapter published by chaukhambha visvabharati Orientalia publishers & distributors. Varanasi.reprint 2005.

19. <http://www.webmed.com/a-to-zguides/elbow-injuries>.– 11/09/2016, 10:20pm

Corresponding Author:

Dr.Geethakumar,Assistant Professor, Department of Rachana Shareera Sri Jayendra Saraswathy Ayurveda College, Chennai.

Email: drgeethakumar@gmail.com

Source of support: Nil

Conflict of interest: None

Declared