

EFFICACY OF *SAMUDRA LAVANA* IN THE MANAGEMENT OF ANUNNAT NABHI WITH SPECIAL REFERENCE TO UMBILICAL GRANULOMA IN NEONATE

¹Gaikwad. Shilpa Tryambakrao

²Raut Aparna Abhay

¹P.G.Scholar of Shalya Tantra Samanya Department

²M.S.Shalya Tantra Samanya, H.O.D and Professor of Shalyatantra Samanya Department, S.S.A.M and Hospital Panchavati, Nashik

ABSTRACT

Umbilical granuloma is the common umbilical condition in neonates, in *Ashtanga hridaya* Acharya Vagbhata explains two *nabhirogas unnat nabhi* and *anunnat nabhi* from which we can correlate *anunnat nabhiroga* with umbilical granuloma. Umbilical granuloma causes inflammation and persistent drainage .umbilical granuloma forms within first week after cord separation. If umbilical granuloma remains untreated it can ooze and cause persistent irritation for several days or months, umbilical granuloma look like moist and reddish tiny granular structure like ball .Size of umbilical granuloma ranges in between 1 mm to 10 mm. The most common treatment used to treat umbilical granuloma are chemical cauterization with silver nitrate or copper sulphate, electric cauterization, cryo cauterization, surgical excision, which causes irritation to patients and also it is very costly treatment and use of *samudralavana* treating umbilical granuloma is simple, can be performed by Non- medico person at home like mother, caretaker, and it is also cost effective & safe.

Keywords: Umbilical Granuloma, *Anunnat Nabhi*, *Samudralavana*, Sodium Chloride.

INTRODUCTION: *Acharya vagbhata* explains two *nabhirogas* in *Ashtanga sangraha*.i.e.1) *Unnat Nabhi* 2) *Anunnat nabhi* ^[1].*annunnat nabhi* is similar to umbilical granuloma. *Anunnat nabhi* (Umbilical granuloma) is the most common umbilical condition in neonates ^[2].The *anunnat nabhi* (umbilical granuloma) looks like a ball of moist, red lump of tissue on the navel. It is an overgrowth of tissue that develops during the healing process of the umbilicus, usually in reaction to a mild infection. It typically presents as a tiny segment of bright red, slightly wet flesh that remains in the umbilicus after cord separation ^[3]. Umbilical granulomas occur in about 1 in 100 neonates .Umbilical granuloma are generally harmless to the baby, but they can cause parents a lot of anxiety due to continuous discharge, swelling due to

infection, or that the site is painful and irritated, or about the appearance. It can be seen in the first few weeks of life, after the umbilical cord has dried and fallen off. It is usually a minor problem that looks worse than it is. An umbilical granuloma does not cause pain as it contains no nerves and is devoid of sensation^[2].It is not a congenital abnormality but represents continuous swelling of the granulation tissue that has not yet epithelialized^[4] .The umbilical cord normally separates within 7–10 days postpartum^[5].Following cord separation, incomplete epithelialization occurs at the fibro muscular ring of the umbilicus, normal granulation tissue of the umbilical stump of a neonate should vanish by the second or third week of birth if there is unhygienic condition then it will lead to an umbilical granuloma.

Additional symptoms may include:

- 1) Oozing
- 2) The presence of sticky mucus
- 3) Mild irritation of the skin around the navel [6].

Presence of the umbilical granuloma beyond its normal time will require Therapeutic treatment [7].

The therapeutic treatments for umbilical granuloma are the

- 1) Chemical cauterization with silver nitrate or copper sulphate,
- 2) Electric cauterization.
- 3) Cryocauterization
- 4) Surgical excision
- 5) Double-ligature technique.

But these treatments can cause minor burns in the periumbilical skin [12] in *ashtanga hridaya vagbhata* had explained properties of *samudralavana* that is *guru gunatmak, vrushya, hrudya, tridosha nasahak* [8]. *Vipaka* of *samudralavana* is *madhura* [9]. In 1972, Schmitt briefly described the contracting effect of common salt on umbilical granuloma [10].

AIM: To assess the efficacy of *samudralavana* in the management of *anunnat nabhi* (umbilical granuloma) in neonates.

MATERIAL & METHOD:

STUDY DESIGN: Prospective Study

STUDY SET UP: This prospective study was conducted on 10 neonates (both sex) of the age (2 to 4 weeks) with umbilical granuloma at Shree Saptashrunji Ayurveda mahavidyalaya and hospital Nashik.

CRITERIA FOR SELECTION OF PATIENTS

Inclusion criteria

- 1) Patient suffering from umbilical granuloma
- 2) Patient of age group between 2 to 4 weeks irrespective of gender.

- 3) Patient of parents who agreed for treatment with informed consent.

Exclusion criteria

- 1) Patient suffering from any other dermal lesion.
- 2) Patient of age group less than 2 week or more than 4 week.
- 3) Patients whose parents are not willing to give consent.

DRUG USED: *Samudralavana*

ROUTE OF APPLICATION: Local application

METHODOLOGY:

- Treatment is application of *samudralavana* on affected part (i.e. Umbilical granuloma) only once.
- After cleaning the umbilical area with a cotton ball soaked in warm water we applied a small pinch *samudralavana* over that *anunnat nabhi* (umbilical granuloma) very carefully because if it is placed on surrounding normal tissues it can causes discoloration so hands on training and much more practice required to do this procedure accurately. This procedure was repeated only if necessary.
- All neonates follow-up done after 3rd day and 7th day to see the effect of *samudralavana* on *anunnat nabhi* (umbilical granuloma).

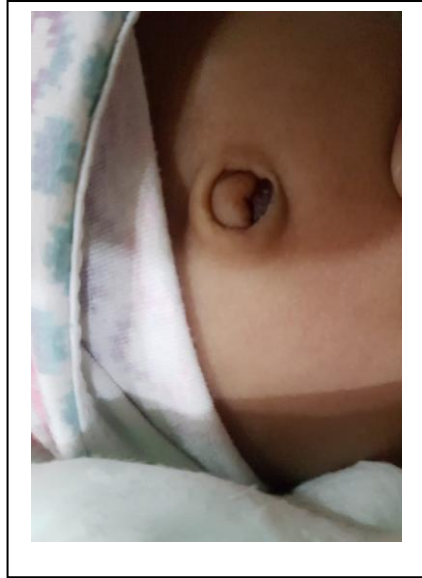
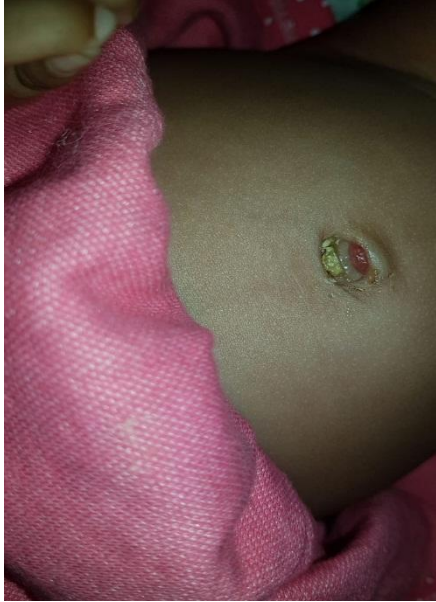THE EFFECTS WERE GRADED AS :

- A) Excellent response** (no discharge, and healed with complete epithelialization)
- B) No response** (no healing of umbilical granuloma, and persistent umbilical discharge).

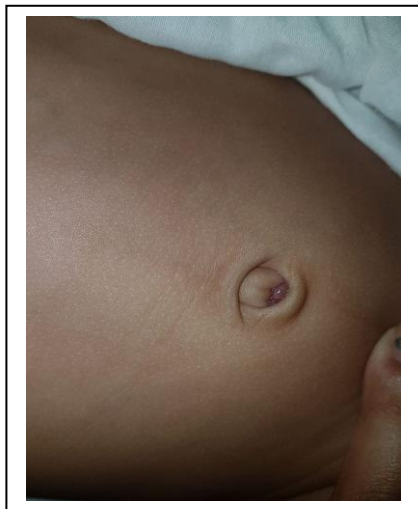
RESULT: All of 10 neonates with umbilical granuloma showed complete resolution after treatment. During study no adverse effects of *samudralavana* were observed. Due to properties of *samudralavana* normal shrinkage and gradual healing of the lesion was

appearing within 1 week. The umbilicus returned to normal condition in all 10 neonates.

DAY 1(BEFORE TREATMENT) DAY 2 (AFTER TREATMENT)



DAY 3 (AFTER TREATMENT)



DISCUSSION:CHART 1: AGE GROUP OF PATIENTS (N=10)

| SR.NO | AGE GROUP OF PATIENT | NO.OF PATIENT | THE PERCENTAGE |
|-------|----------------------|---------------|----------------|
| 1. | 2-3 WEEKS | 03 | 30% |
| 2. | 3-4 WEEKS | 07 | 70% |

CHART 2: RESPONSE TOWARDS TREATMENT

| SR.NO | RESPONSE | NO.OF PATIENT | THE PERCENTAGE |
|-------|-------------|---------------|----------------|
| 1. | EXCELLENT | 10 | 100 |
| 2. | NO RESPONSE | 0 | 0 |

The umbilical granuloma is the most common umbilical condition in neonates. If umbilical granuloma remains untreated, it can ooze and present with persisting irritation for several weeks or months^[10]. There are many treatments available for umbilical granuloma such as chemical cauterization, electro cauterization, cryocauterization, granuloma ligation, and surgical excision, but each and every method has certain advantages and disadvantages also. Cauterization with silver nitrate or copper sulphate may cause a cloth staining and also minor burn on the periumbilical skin, which is painful^[11] cryocautery is expensive, electro cautery is associated with a foul discharge and higher failure rates and surgical treatment needs general anesthesia^[4] So *samudralavana* is a suitable agent for the treatment of umbilical granuloma. *Samudralavana* is potent and cost-effective, shows no adverse effects, and easily available. This study reveals treating umbilical granuloma with *samudralavana*. A total 10 neonates of the ages 2 to 4 weeks were selected for the study. This study was conducted over 6 months of duration, All 10 neonates enrolled in this study showed excellent results. Umbilical granuloma is effectively and easily managed by local application of *samudralavana*. The umbilical granuloma treated with *samudralavana* usually clears within 3–5 days. The curative mechanism of salt when used for treating umbilical granuloma is attributed to its desiccant effect and other biological properties. The high concentration of sodium ion in the area draws water out of the cells and results in shrinkage and necrosis of the wet granulation tissue. This effect is not so strong as to cause damage to the normal surrounding tissue when applied for short

treatment duration. Use of *samudralavana* does not have any complications and can be applied easily by parents and no need of physician. The procedure is not painful as the umbilical granuloma contains no nerves and so no sensation. *Samudralavana* is not an irritant to tissues and does not burn normal tissues this study reveals the successful treatment of umbilical granuloma with *samudralavana* with no adverse effects or complications.

CONCLUSION: The use of *samudralavana* in treating umbilical granuloma is simple, cost effective, without any adverse effects or complications, curative and safe. This treatment can be performed by Non-medico person like mother, caretaker etc. at home

REFERENCES:

- 1) Dr. Ashok More, Kaumarbhritya , Advait Publication, Chapter no17, Prasavottar Vyadhi, Page No: 343
- 2) KA O'Donnell, Glick PL, Caty MG. Pediatric umbilical problems, Pediatric Cline North Am 1998; 45: 791–99.
- 3) Assi AN, MK Kadem. Management of umbilical granuloma. Thi-Qar Medical Journal (TQMJ) 2010; 4(4):82–7.
- 4) Pomeranz A. abnormalities Anomalies and care of the umbilicus. Pediatric Clinic North Am 2004; 5 1(3):819–27.8
- 5) Ochs HD Wilson CB, Almquist J, Dassel S, Mauseth R. When is umbilical cord separation delayed? J Pediatric 1985 107: 292–4.5. Vicente Pediatric Surgery Update 2004; 2 2(3): 65–.
- 6) <https://www.medicalnewstoday.com/articles/321741.php#symptoms> 08/05/2018
- 7) Vicente H (Ed). Pediatric Surgery 2004; 2 2(3):65–6

- 8)shree vagbhatavirachit ,ashtanga hridya,gadgil,chaturth avrutti,2017,chap 6,shloka no:144,pg no:128,129
- 9) Dr.Ravi Dutta Tripathy, srimad vriddha vagbhata virachita, ashtanga sangria sutrasthana, chap12, shloka 34, page no: 244
- 10)<https://www.ejmanager.com/mnstemps/67/67-1452639453.pdf?t=1579625200> 18/01/2016
- 11) Chamberlain JM, Gorman RL, Silver nitrate burns following treatment for umbilical granuloma. Pediatric Emergency Care 1992; 8(1):29–30
- 12) Campbell J, Beasley SW, Huston JM, McMullen N, Clinical diagnosis of umbilical swellings and discharges in children. Med journal 1986; 145(9):450–3.

Corresponding Author:

Dr Shilpa Tryambakrao Gaikwad.

P.G.Scholar of Shalya Tantra Samanya Department S.S.A.M and Hospital Panchavati, Nashik

Email: shilpagaikwad77@gmail.com

Source of support: Nil Conflict of interest:
None Declared

Cite this Article as :[Gaikwad. Shilpa Tryambakrao et al : Efficacy of Samudra Lavana in the Management of Anunnat Nabhi With Special Reference to Umbilical Granuloma in Neonate] www.ijaar.in : IJAAR VOLUME IV ISSUE VI JAN –FEB 2020 Page No: 563-567