

**VARIATION IN THE MUSCULOCUTANEOUS NERVE – A CASE STUDY**

Mithanthaya Seetharama<sup>1</sup>, Shah Rutva<sup>2</sup>, Patel Archana<sup>3</sup>, Sutariya Manoj<sup>4</sup>, Murli Ram<sup>5</sup>

<sup>1</sup>Reader, Dept of Rachana Sharira, J.S.Ayurveda Mahavidyala, Nadiad.

<sup>2,3,4,5</sup> PG Scholar, Dept of Rachana Sharira, J.S.Ayurveda Mahavidyala, Nadiad.

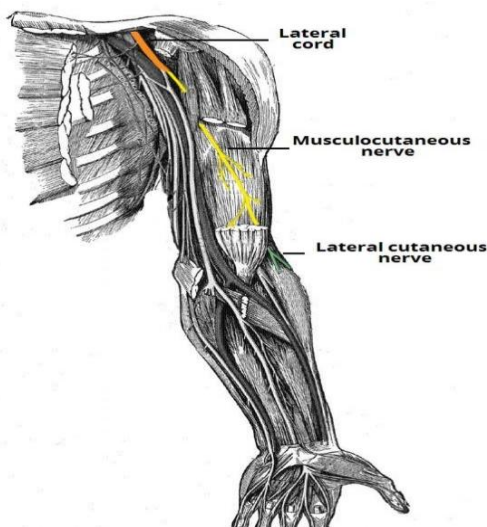
**ABSTRACT**

Variations of the musculocutaneous nerve (MC) are not common. In normal individuals the musculocutaneous nerve is the terminal branch of the lateral cord of the brachial plexus. The present paper is to document the variation in the musculocutaneous nerve (MC) which the authors encountered during the routine dissection. In the routine postgraduate dissection, it was found that the lateral root of median nerve gave a muscular branch to the coracobrachialis muscles and musculocutaneous nerve got originate from the ulnar nerve which supply the biceps brachii and brachialis muscles. Knowledge of these variations is important to the anatomists, orthopedicians, neurologist and anaesthetist.

**Keywords:** *Musculocutaneous nerve (MC), Coracobrachialis muscles, Ulnar nerve.*

**INTRODUCTION:** Musculo – cutaneous nerve (MC) is the nerve of flexor compartment of arm and derived from the lateral cord of brachial plexus. It conveys the fibres from C5, C6, and C7 spinal nerves. The nerve initially accompanies the third part of axillary artery on its lateral side and pierces the coracobrachialis muscle. It

**Fig 1: Normal course of musculocutaneous nerve**



gives a branch to the coracobrachialis even before piercing the muscle and the fibres are derived from C7.

The nerve then courses downwards and laterally lying between the biceps brachii and brachialis. It gives branches to both the heads of the biceps and medial major part of the brachialis; through the nerve to the brachialis it gives articular twigs to the elbow joint and a nutrient branch to the humerus<sup>1</sup>.

Just below the elbow, lateral to the tendon of biceps brachii it pierces the deep fascia, and extends further downward as the lateral cutaneous nerve of the forearm to supply the skin of the antero-lateral region of fore arm as far distally as the base of the thenar eminence<sup>2</sup>.

**CASE REPORT:** A variation in the musculocutaneous nerve was found during routine dissection of the left upper limb of an 85 years old male cadaver at P. G. Department of Rachana Sharir, J.S.Ayurveda Mahavidyalaya , Nadiad, Gujarat, India. Before dissection the corpse

was preserved in a solution of formaldehyde and glycerine. The dissections of upper limbs were carried out according to the Cunningham's manual of practical anatomy. Coracobrachialis muscles and musculocutaneous nerve got originate from the ulnar nerve which supplies the biceps brachii and brachialis muscles. Later the nerve continues as lateral cutaneous nerve of forearm.

**DISCUSSION:** The variation in the branching pattern of brachial plexus is very common. In present case the nerve to coracobrachialis took its origin from lateral root of median nerve and musculocutaneous nerve (MC) arise from ulnar nerve.

In the study of Choi et al., communication of the median and musculocutaneous nerves were observed in 26.4% of 138 arms. The nerves were either fused, or communicating branches from the musculocutaneous nerve to the median nerve<sup>3</sup>. Venieratos and Anagnostopoulou observed connections between the median and musculocutaneous nerves in 22 (13.9%) cases out of 158 upper extremities. The origin of the connection was distal to the coracobrachialis muscle<sup>4</sup>. In the study of Prasada Rao and Chaudhary, communicating branch from the musculocutaneous nerve to the median nerve was observed in 33% on 24 upper arms, but there wasn't any anastomotic branch between median nerve and musculocutaneous nerve<sup>5</sup>. Loukas and Aqueelah In 63.5% cases found the communicating branch between the median and musculocutaneous nerves, most of these connections located proximal to the entry of

This paper reports a variation of the musculocutaneous nerve. It was noticed that the lateral root of median nerve gave a muscular branch to the musculocutaneous nerve into the coracobrachialis muscle<sup>6</sup>. Beheiry observed presence of communicating branch from the median nerve to the musculocutaneous nerve in 5% limbs<sup>7</sup>. Kosugi et al. reported communicating branch arising from the median nerve was found in 16% of the cases with a supernumerary head of biceps brachii muscle<sup>8</sup>. Virendra et al found the absence of musculocutaneous nerve in 13 out of 116 (11.2%) specimens, where median nerve innervated *biceps brachii* and *brachialis* muscle. They observed *coracobrachialis* muscle. They observed *coracobrachialis* muscle was innervated by a direct branch from the lateral cord of brachial plexus. Median nerve divide in the arm into a lateral and a medial divisions, Lateral division continued as musculocutaneous nerve and the medial division as median nerve proper, in 5.12% specimens and observed type II communications in 20.7% specimens<sup>9</sup>. Guerri- Guttenberg and Ingolotti (2009) reported communications between musculocutaneous and median nerve in 53.6% dissections; of these, 84.6% were proximal, 7.7% distal, and 7.7% both proximal and distal to the point of entry of musculocutaneous nerve into coracobrachialis muscle<sup>10</sup>.

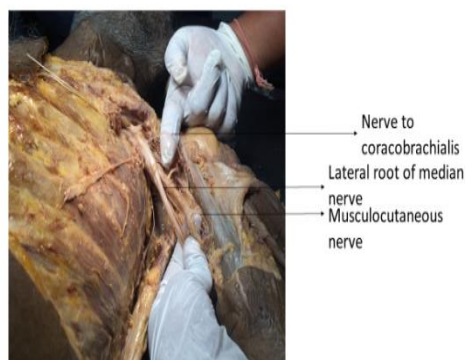


Fig:2



Fig:3

Figure – 2 : Nerve to coracobrachialis emerge from lateral root of median nerve and : Nerve to brachialis and biceps brachii emerge from ulnar nerve .

Figure -3. Final termination of Musculocutaneous nerve

Author's Name	Absence of musculocutaneous nerve	Splitting of median nerve in the arm	Communication branch between musculocutaneous nerve and Median nerve
Virendra et al	11.2%	5.12%	20.7% (Type-2)
Guerri et al	-	-	7.7% 84.6%(Type-1)
Choi et al	-	-	26.4%
Venieratos et al	-	-	13.9%(Type -2)
Prasada rao et al	-	-	33%
Loukas et al	-	-	63.5%
Beheiry et al	-	-	5%
Kosugi et al	-	-	16%

Type-1 = Communication proximal to entrance musculocutaneous nerve into the coracobrachialis muscle.

Type-2 = Communication distal to musculocutaneous nerve exit from the coracobrachialis muscle.

The variations of MC are clinically important for surgeons, orthopaedists, and anaesthetists performing pain management therapies or regional anesthesia to the upper limb. On the one hand, during flap dissections, unexpected nerve damages could arise especially by surgeons who are familiar with routine course of peripheral nerves and their relationship with

neighbouring structures but inexperienced in variations<sup>11</sup>. An isolated injury to the musculocutaneous nerve is rare, but may occur during injuries to the upper arm and shoulder, e.g. fracture of the humerus and in patients with neuralgic amyotrophy. There is much weakness of the elbow flexion as biceps brachii and much of the brachialis are paralyzed with sensory impairment on the extensor aspect of forearm in the distribution of the lateral cutaneous nerve of the forearm<sup>12</sup>. Hence, a knowledge of such variation is important for surgeons to be aware of possible anatomical variations to avoid unexpected

complications, especially in post-traumatic evaluations and exploratory interventions of the arm for peripheral nerve repair, during flap dissections by plastic surgeons or during the performance of axillary blocks by anesthetists<sup>13</sup>. Different communications involving musculocutaneous nerve are important in repairs for trauma to the shoulder and also in understanding of the musculocutaneous nerve dysfunction<sup>14</sup>. A more precise knowledge than that found in classical anatomical texts is necessary for clinical investigation and the surgical treatment of peripheral nerve injury<sup>15</sup>.

The embryological development of the upper limb may help in explaining neurological variations. Mesenchyme, which comes from the dorsolateral part of the somites, migrates and forms the muscles into the limb bud. At the same time, the mesenchyme is penetrated by the ventral primary rami of the appropriate spinal nerves, located opposite to the bud. Contact between nerves and muscle cells are necessary to provide mesenchymal condensation to form muscles. Nerves supplying the limbs are joined by connecting loops of nerve fibres to form plexuses. The median nerve is formed by a combination of ventral segmental branches and the musculocutaneous nerve arises from it<sup>16</sup>. The Brachial plexus is formed by the lower five cervical ventral rami with a variable contribution from C4 and T2. In humans, the forelimb muscles develop from the mesenchyme of the paraxial mesoderm during the fifth week of intrauterine life<sup>17</sup>. The existence of variations described may be due to altered signalling between mesenchymal cells and normal growth cones or circulatory factors at the time of gene controlled site specific formation of the cords of the brachial

plexus usually during 4th to 7th week of intrauterine life<sup>18</sup>. The embryological development of the upper limb may help in describing this anatomical variation. Mesenchymal, which comes from the dorsal lateral part of the somites, immigrates and forms the muscles into the limb bud. Disturbances in these process, taking place in the 4th-7th weeks of development lead to anatomical variation in the innervations of the muscles by appropriate nerves<sup>19</sup>. Understanding the embryologic development of the brachial plexus is important in explaining the origin of possible anatomic variations. The human upper limb bud appears at 26-27 days in the developing embryo and motor axons arising from the spinal cord enter the limb buds during the fifth week<sup>20</sup>. Formation of the brachial plexus is evident from about 34-35 days as a single radicular cone in the upper limb. At between 38 and 40 days, the major branches of the brachial plexus become visible, and the median, radial and ulnar nerves enter the hand plate<sup>21</sup>. The brachial plexus is divided into ventral and dorsal segments and the ventral segment that give roots to the median and ulnar nerves. The musculocutaneous nerve arises from the median nerve<sup>22</sup>.

**CONCLUSION:** Musculocutaneous nerve is one among the prime nerve of flexor compartment of arm. There is no variation found that musculocutaneous nerve arises from ulnar nerve. The knowledge of such variations helpful for performing pain management therapies or regional anaesthesia to the upper limb.

#### **REFERENCES:**

- 1 .A.K. Datta. Essentials of Human Anatomy. Vol-3. 4th ed. Kolkata: Current Books International; 2009 p 50
- 2.Gray's anatomy : 40<sup>th</sup> edition:2008: Elsevier limited :821

3. Choi D, Rodriguez-Niedenfuhr M, Vazquez T, Parkin I, Sanudo JR. Patterns of connections between the musculocutaneous and median nerves in the axilla and arm. *Clin Anat* 2002;15:11-7.
4. Venieratos D, Anagnostopoulou S. Classification of communications between the musculocutaneous and median nerves. *Clin Anat* 1998; 11: 327-31.
5. Prasada Rao PV, Chaudhary SC. Communication of the musculocutaneous nerve with the median nerve. *East Afr Med J* 2000; 77: 498-503.
- 6 . Loukas M, Aqueelah H. Musculocutaneous and median nerve connections within, proximal and distal to the coracobrachialis muscle. *Folia Morphol* 2005; 64: 101-8.
- 7 . Beheiry EE. Anatomical variations of the median nerve distribution and communication in the arm. *Folia Morphol* 2004; 63: 313-8.
8. Kosugi K, Shibata S, Yamashita H. Supernumerary head of biceps brachii and branching pattern of the musculocutaneous nerve in Japanese. *Surg Radiol Anat* 1992; 14: 175-85.
9. Virendra Budhiraja, Rakhi Rastogi, Ajay Kumar Asthana, Priti Sinha, Atul Krishna, Vikas Trivedi. Concurrent variations of median and musculocutaneous nerves and their clinical correlation– a cadaveric study . *Basic and Applied Anatomy*, 2011; 116:67-72.
- 10 . Guerri-Guttenberg R.A., Ingolotti M. (2009) Classifying musculocutaneous nerve variations. *Clin. Anat.* 22: 671-683.
- 11 . Ibrahim CH, Adnan E, Cem DC (2005) Variation between median and musculocutaneous nerves. *Internet J Surg* 6: 11.
12. Standring S, Johnson D, Collins P, Healy JC, Lee J(editors). In: 'Gray's Anatomy, The Anatomical Basis of Clinical Practice'. Pectoral Girdle, Shoulder Region and Axilla. 40th Edition. Spain, Churchill Livingstone Elsevier, 2008; 821-22.
- 13 . Ray A, Bhattacharya S, Dutta S, Mandal L, Majumdar S. An evaluation of the system of classifications of the median and musculocutaneous nerves: A study in West Bengal population. *Indian Journal of Basic & Applied Medical Research*. September 2013;8(2), P. 841-53.
14. Chitra R. Various types of intercommunications between musculocutaneous and median nerves: An analytical study. *Annals of Indian Academy of Neurology*. 2007;10:100-4.
15. Linell EA. The distribution of nerves in the upper limb, with reference to variabilities and their clinical significance. *Journal of Anatomy*. 1921;55:79-112
- 16 . Patel SJ, Patel RK, Bhatt C, Mehta CD. Variation of musculocutaneous nerve in arm with additional muscular slip in forearm. *International Journal of Anatomy and Physiology*. March, 2013. Vol. 2 (3):20-22.
17. Gupta C, D'Souza AS, Shetty P, Vidya P, Arunashri. A morphological study to note the anatomical variations in the branching pattern of the lateral cord of the brachial plexus. *Journal of Morphological Science*. 2011; 28(3): 161-64.
- 18 . Durgesh V, Ramana Rao R. Musculocutaneous nerve revisited. *International Journal of Basic and Applied Medical Sciences*. Online International Journal : 2013 Vol. 3 (2) May-August, pp.34-36. Available at <http://www.cibtech.org/jms.htm>.
- 19 . Rodriguez-Niedenfuhr M, Vázquez T, Choi D, et al. Supernumerary humeral heads of the biceps brachii muscle revisited. *Clin Anat*. 2003;16(3):197–203.

20 . Moore KL, Persaud TVN. The developing human: clinically oriented embryology. 6th ed. Philadelphia: W.B. Saunders Company; 1998

21 . O’Rahilly R, Gardner E. The timing and sequence of events in the development of the limbs in the human embryo. Anat Embryol 1975; 148: 1-23. 15.

22 . Windle WF, Fitzgerald JE. Development of the spinal reflex mechanism in human embryos. J Comp Neurol 1937; 67: 493-509 [cited In: Paxinos G, Mai JK, editors. The human nervous system. San Diego: Elsevier; 2004. p. 103.]

---

**Corresponding Author:**

Dr. Seetharama Mithanthaya, Reader, Dept of Rachana Sharira, J.S.Ayurveda Mahavidyala, Nadiad.

Email: rutvashah3012@gmail.com

---

Source of support: Nil

Conflict of interest: None

Declared

*Cite this Article as : [Mithanthaya Seetharama et al: Variation in the Musculocutaneous Nerve – A Case Study] www.ijaar.in : IJAAR VOLUME IV ISSUE I MARCH – APRIL 2019 Page No:49-54*