

## LOHITAKSHA MARMA: A STUDY BASED ON DISSECTION IN LOWER LIMB

Jain Teena<sup>1</sup>

Yadav Sunil Kumar<sup>2</sup>

<sup>1</sup>Ph.D. Scholar, Dept.of *Sharir Rachana*, NIA, Jaipur.

<sup>2</sup>Assistant Professor, Dept.of *Sharir Rachana*, NIA, Jaipur.

### ABSTRACT :

*Marma* are very sensitive, tender and vulnerable points in the human body. Therefore, it is very essential to protect them from any injury or trauma during surgical operations, medical treatments, exercise and day-to-day practice of various arts including martial arts. The knowledge of vital points of the body is defensive mechanism which enables the medicine to set the lines during management either by medicinal or surgical discipline. The *Marma* are said to be '*Jivasthana*' and are 107 in numbers. They are distributed throughout the human body. The *Marma Sharira* has been explained by *Sushruta* in "*Pratyekamarmanirdesha Sharira*" and *Vagbhata* in *Marmavibhagam Shariram*. *Marma* are said to be the sites where there is the conglomeration of *Mamsa*, *Sira*, *Snayu*, *Asthi* and *Samdhi* and at these places *Prana* resides specially by nature. *Lohitaksha Marma* is the *Vaikalyakar Marma* which is located in lower limb two inches lateral to pubic symphysis where femoral artery passes in femoral triangle.

**Key words:** *Marma*, *Lohitaksha Marma*, Femoral triangle and femoral vessels.

**INTRODUCTION:** Man has to deal with the manifold problems on daily basis with virtue of his experience and adaptability. Human race is burdened with many problems and medical related problems are of more concern. The health is obtained by simply following the rules and regulations of *Ayurveda*. *Ayurveda* is the oldest science of medicine, which exists even in *Rigveda*. The fundamental philosophy of *Ayurveda* reveals the forces which control the universe and can be illustrated in the human body also. As human being is micro replica of the universe.<sup>1</sup> Nature's Sun, Moon and wind are resembled in the human beings by *Pitta*, *Kapha* and *Vayu* humour. The conduction, regulation movement, transaction and integration of all vital functions of the body perform through the vital points, on which life locates.<sup>2</sup>

The prime goal of any physician / surgeon is to save "*Prana*" or life or *Ayu* or the

energy. This is why *Ayurveda* considers that "*Praneshana*" is the utmost requirement in *Trieshana*.<sup>3</sup> *Ayurveda* narrates that the vital points of our body in terms of *Marma* are the seat of *Prana* which sustain energy of health and enlighten the life in healthy state. The *Marma* are said to be '*Jivasthana*' and are 107 in numbers. They are distributed throughout the human body. The *Marma Sharira* has been explained by *Sushruta* in "*Pratyekamarmanirdesha Sharira*" and *Vagbhata* in *Marmavibhagam Shariram*.

**Etymology:** *Marma* is derived from the root '*mrna pranatyage*'<sup>4</sup> meaning, that which cause *pranathyaga* or death. *Marma* means tender, vital, vulnerable, valuable, live seat of the body imbedded, not exposed, not derived, centre point or nodal point of any liveliness, which can be experienced.

**Definition:** *Marma* is defined as anatomical site where *Mamsa*, *Sira*, *Snayu*,

*Asthi* and *Samdhi* meet together and at these places *Prana* resides specially by nature.<sup>5</sup> *Marma* are the points where not only “*Tridosha*” but their subtle forms *Prana*, *Ojus* and *Tejas* are also present with *Sattva*, *Rajas* and *Tamas*. These specific areas on the body are related through *Pranic* channel to various internal organs, therefore it is essential to know completely.<sup>6</sup>

In thigh *Lohitaksha Marma* is situated above *Urvi Marma* and below *Vankshana Sandhi* at the root of the *Uru*. *Lohitaksha Marma* is *Vaikalyakara* in *Parinama*. Depending upon the structural classification, the *Lohitaksha Marma* is explained as *Sira Marma* by *Sushruta* and *Vagbhata*.

**Need of Study:** *Lohitaksha Marma* is *Vaikalyakara Marma*. Any injury to this *Marma* does not result in death but always cause a deformity that may persist forever. Thus, this topic is selected for study to correlate with modern anatomy, so that the actual structures present at those sites which injured and causes loss of blood leading to wasting of the muscles or thinning or the *Sakthi* (lower limb).

**MATERIALS AND**

**METHODOLOGY:**

**MATERIALS:**

- For literary study:- Available literature regarding *Lohitaksha Marma* from *Ayurvedika* texts and Modern texts.
- For cadaveric Study:-
  1. Cadaver: Either male or female.
  2. Dissection kit

**METHODOLOGY:**

**Literature Study:** All the information regarding *Lohitaksha Marma* along with anatomy of femoral triangle was collected from *Ayurveda* texts and modern texts.

**Cadaveric Study:** - Dissection was done in the dissection hall of department of *Sharir Rachana* of NIA, Jaipur. While studying the dissected cadaver, photo images were taken with the help of digital camera.

Cadaver was selected based on the inclusion and exclusion criteria explained below-

• **Inclusion Criteria:-**

- Cadaver with fully developed body part.
- Cadaver of either sex.
- Having natural death.
- Preserved by proper methods of preservation.

• **Exclusion Criteria:** - Death due to poisoning, accidental condition and any chronic disease conditions.

Dissection of the femoral triangle was done on cadaver by using dissection kit; Cunningham's manual of practical anatomy, Grant's Dissector, Frank H. Netter and B. D. Chaurasia's Human Anatomy for understanding the *Lohitaksha Marma*. Superficial and deep dissection is done carefully to study the structures present at the marked site.

**OBSERVATIONS:** The term *Lohitaksha* literally symbolism with *Lohita* means blood and *Aksha* means eye, and is located above the *Urvi Marma*.<sup>7</sup> The *Marma* is very easy to locate at the top of thigh. It lies near the great inguinal canal through which the femoral vessels emerge from abdominal cavity. As an injury to this leads to profuse bleeding.

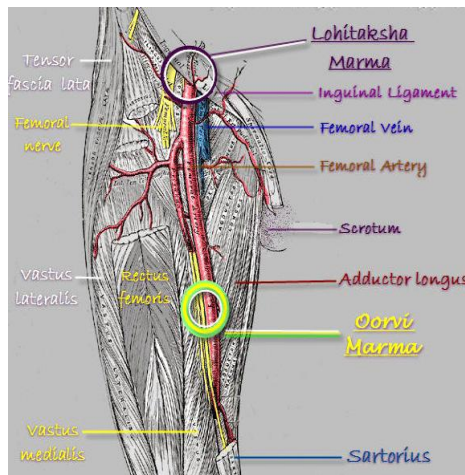


Fig. 1 Location of *Lohitaksha Marma*

By considering all these points, a region was marked on cadaver in the femoral region. On the detailed dissection of the marked region following structures were seen from outside to inside-

- a) Skin
- b) Superficial fascia- contents lateral femoral cutaneous nerve, anterior cutaneous branches of the femoral nerve, superficial veins.
- c) Deep fascia or fascia lata
- d) Femoral triangle- The femoral triangle is bounded superiorly by the inguinal ligament, laterally by the medial border of the Sartorius muscle and medially by the medial border of the adductor longus muscle. The base of the femoral triangle is the inguinal ligament and the apex is located inferiorly.

The contents of the femoral triangle are the:

- Femoral nerve and its branches
- Femoral artery and some of its branches
- Femoral vein and some of its tributaries (notably, the great saphenous vein)

• Femoral sheath- The femoral sheath envelops the femoral artery, femoral vein, and some deep inguinal lymph nodes. The femoral sheath is subdivided into three compartments:

- **Lateral Compartment**– containing the femoral artery.
- **Intermediate Compartment** – containing the femoral vein.
- **Medial Compartment** – containing lymphatics. The medial compartment of the femoral sheath is called the femoral canal and its proximal opening is called the femoral ring.

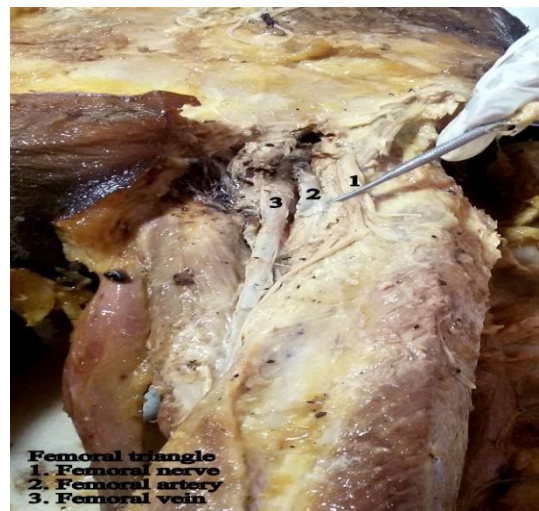

Fig. 2 Femoral triangle

**DISCUSSION:** The study was carried out in two parts literature study and cadaveric study. *Lohitaksha Marma* is situated above *Urvi Marma* and below *Vankshana Sandhi* (hip joint) at the root of the *Uru*. On injury this causes paralysis of the muscles or thinning of the *Sakthi* (lower limb) due to loss of blood. Based on predominance of Material Matrix or anatomical structure, it is *Sira Marma*. On the basis of fatal effect of injured *Marma*, *Lohitaksha Marma* is *Vaikalykara Marma*. *Vaikalykara Marma* are those *Marma* which are having union of three belonging to the anatomical matrix. *Vaikalykara Marma* are dominated by the attributes of *Jala Mahabhuta*. *Jala Mahabhuta* is stable and cooling. Therefore, any injury to this *Marma* does not result in death but always cause a deformity that may persist forever. Total number of *Lohitaksha Marma* is four - 1 in each limb.<sup>8</sup>

The *Marma* is very easy to locate at the top of the thigh. *Lohitaksha Marma* is present near the great inguinal canal through which the femoral vessels emerge from abdominal cavity and it is completely formed by femoral triangle. The femoral artery and vein run along the bottom of the femoral triangle along a boundary line that separates to independent motor nerve

territories the femoral vein in its upper part lies medial to the femoral artery in the femoral triangle but comes posterior due to intrauterine lateral rotation of the limb and at the apex the relationship between artery and vein is antero-posterior; so does, also, the profunda vessels, thus all four vessels are in antero-posterior relationship within the femoral sheath. An injury therefore, injures the structures running under the apex. The femoral nerve breaks up in thigh like cauda equina into numerous motor & sensory strands. Two of these follow the artery, closely applied to its lateral side, into the adductor canal; one nerve to the vastus medialis is motor; the other saphenous nerve is sensory.

The femoral vessels are the continuation of the vessels from the trunk. At the root of the limb they are fixed and easily injured being most superficial. The trauma of this *Marma* produces mainly two events. The first event is severe hemorrhage, which is seen just after the injury. The injury to the nerves or pressure on the nerve due to large hemorrhage may be seen in later stage.

**CONCLUSION:**

*Lohitaksha Marma* is located above the *Urvi Marma* and below the *Vankshana Sandhi* at the root of *Uru*. It lies 2 inches

lateral to pubic symphysis where femoral artery passes in femoral triangle. So it is a part of femoral triangle and the main structures found at this region are-

- a) Skin
- b) Superficial fascia- contents lateral femoral cutaneous nerve, anterior cutaneous branches of the femoral nerve, superficial veins.
- c) Deep fascia or fascia lata
- d) Femoral nerve and its branches
- e) Femoral artery and some of its branches
- f) Femoral vein and some of its tributaries

In *Lohitaksha Marma*, the word *lohita* indicates reddish or blood and based on predominance of Material Matrix or anatomical structure, it is *Sira Marma*. So when injury occur at this site causes loss of blood from femoral vessels leading to wasting of the muscles or the thinning of the *Sakthi* due to pressure on the nerves by hematoma. The motor paralysis may produce disuse atrophy of the muscles whereas arterial insufficiency may lead to dry gangrene later on.

#### REFERENCES:

1. Charaka Samhita (Agnivesh) Part 1- elaborated vidyotini Hindi Commentary by pt. kasinatha sastri and dr. gorakha natha chaturvedi, Published by Chaukhambha Bharati Academy, Gokul Bhawan, Gopal Mandi Lane, Varanasi, 2005, Page No. 709.
2. Dalhana, Nibandhasangraha Commentary of Sushruta, edited by Vaidya Jadavji Trikamji Acharya and Narayan Ram Acharya, Chaukhamba Surbharti Prakashan, Varanasi, 2012, Page No. 100.

3. Charaka Samhita (Agnivesh) Part 1- elaborated vidyotini Hindi Commentary by pt. kasinatha sastri and dr. gorakha natha chaturvedi, Published by Chaukhambha Bharati Academy, Gokul Bhawan, Gopal Mandi Lane, Varanasi, 2005, Page No. 207.

4. Amarasimha. Amarakosa, Hargovinda Shastri, Chaukhamba Sanskrit Sansthan, Varanasi, 2006.

5. Dalhana, Nibandhasangraha Commentary of Sushruta, edited by Vaidya Jadavji Trikamji Acharya and Narayan Ram Acharya, Chaukhamba Surbharti Prakashan, Varanasi, 2012, Page No. 217.

6. Dalhana, Nibandhasangraha Commentary of Sushruta, edited by Vaidya Jadavji Trikamji Acharya and Narayan Ram Acharya, Chaukhamba Surbharti Prakashan, Varanasi, 2012, Page No. 371.

7. Dalhana, Nibandhasangraha Commentary of Sushruta, edited by Vaidya Jadavji Trikamji Acharya and Narayan Ram Acharya, Chaukhamba Surbharti Prakashan, Varanasi, 2012, Page No. 372.

8. Dalhana, Nibandhasangraha Commentary of Sushruta, edited by Vaidya Jadavji Trikamji Acharya and Narayan Ram Acharya, Chaukhamba Surbharti Prakashan, Varanasi, 2012, Page No. 370-375.

**Corresponding Author:** Dr. Teena Jain Ph.D. Scholar, Department of Sharir Rachana, National Institute of Ayurveda, Jaipur, Rajasthan.  
Email- jainteena1186@gmail.com

Source of support: Nil  
Conflict of interest: None  
Declared